

RAPPORT RAPPORT

Structural organisation of proprioceptors in the oculomotor system of mammals

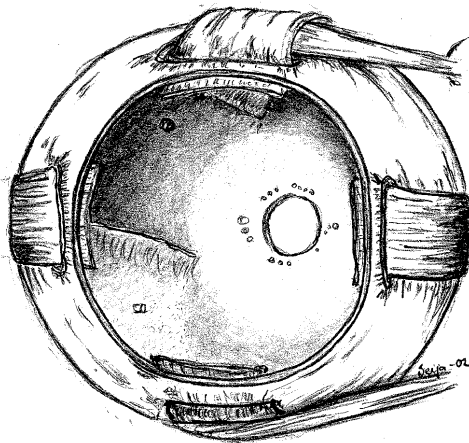
Inga-Britt Kjellevold Haugen (M.Phil)



Rapporter fra Høgskolen i Buskerud

Nr. 37

**Structural organisation of proprioceptors in the
oculomotor system of mammals**



Inga-Britt Kjellevoid Haugen (M.Phil)

Kongsberg 2002

HiBus publikasjoner kan kopieres fritt og videreformidles til andre interesserte uten avgift.

En forutsetning er at navn på utgiver og forfatter(e) angis - og angis korrekt. Det må ikke foretas endringer i verket.

ISBN 82-91116-53-9

ISSN 0807 - 4488

CONTENTS

1. PREFACE	4
2. ACKNOWLEDGEMENT.....	5
3. AFFERENT INNERVATION OF THE EXTRAOCULAR MUSCLES.....	6
3.1 SENSORY NERVE TERMINALS	6
3.2 MUSCLE SENSE AND RECEPTORS IN THE EXTRAOCULAR MUSCLES	8
3.3 MUSCLE SPINDLES	16
3.4 MUSCLE SPINDLES IN EXTRAOCULAR MUSCLES	21
3.5 GOLGI TENDON ORGANS	27
3.6 GOLGI TENDON ORGANS IN EXTRAOCULAR MUSCLES.....	34
3.7 PALISADE ENDINGS AND MYOTENDINOUS CYLINDERS.....	37
4. POSTSCRIPT	45
5. LIST OF ILLUSTRATIONS.....	46
6. LIST OF SYMBOLS AND ABBREVIATIONS USED IN TEXT	47
7. BIBLIOGRAPHY	48

1. Preface

Whether or not proprioception contributes to oculomotor control has been a matter of debate for several years. Extensive studies of mammalian extraocular muscles have significantly increased the knowledge of oculorotatory muscle receptor presence and morphology. A well-documented disparity of muscle receptor complement between species, however, has complicated the comprehension of the potential role of such a feedback system. For example man and sheep have a generous supply of muscle spindles in their extraocular muscles, while monkey, cat and dog have non. A similar disparity obtains for Golgi tendon organs. A modified form of the latter receptor has been described in sheep, whilst myotendinous cylinders have been described in man, cat, sheep and monkey. Furthermore, some of the tendon receptors are exclusively associated with Felderstruktur fibres, which complicates the picture even more.

Since the morphology and distribution of receptors in extraocular muscles seems to be species dependent, one may argue that the nature of the proprioceptive signal also varies from one type of animal to another and assume such variations in afferent signals to have functional implications. Based upon the existing comparative picture of muscle receptor population in the various species, different hypotheses regarding the presence and role of proprioception in oculomotor control have evolved.

The potential implications are not discussed in the current document and remains to be dealt with in future publications. The purpose of this study has primary been to assemble data regarding sensory innervation of extraocular muscles, with emphasis on afferent nerve terminals, and secondarily describe various theories regarding the components contributing to spatial stability and oculomotor control.

This manuscript is a product of thorough reviews of the existing literature as well as examinations of extraocular muscles from man, sheep, cat, monkey, rabbit, guinea pig and rat. The study, which is presented as a literature review, will hopefully be of good use for the reader as a reference manual and facilitate the understanding of the oculomotor control system.

2. Acknowledgement

I wish to express my gratitude to Professor Gordon L. Ruskell at City University, United Kingdom, and to Professor J. Richard Bruenech at Buskerud College, Norway, for their skilful guidance and for placing their expert anatomical knowledge at my disposal.

The financial support provided by the Buskerud College, the Norwegian Optometric Society, the Norwegian Research Institute and J.H.& M. Jansons foundation is also gratefully acknowledged.

3. Afferent innervation of the extraocular muscles

3.1 Sensory nerve terminals

The central nervous system (CNS) records variations within the body and the closest environment by cells, so called sensory receptors, which have differentiated to respond selectively and with great precision to different stimuli. The receptors are present in considerable numbers, and appear in different forms, some being more elaborate than others. They are located throughout the body: in epithelium, muscular tissue, in joints, ligaments, tendons or myotendinous junctions, depending on their role and function.

The receptors detect stimuli either directly by the peripheral end of a sensory neuron itself, by a peripheral nerve ending intermingling among special accessory cells and/or extracellular elements, or by having special, often non-neural, cells detect the stimulus and then activate the peripheral process of the sensory neuron.

Several classification systems, based on different criteria, have been introduced to classify the various receptors. A commonly used system divides receptors according to their distribution in the body: exteroceptors, proprioceptors and interoceptors.

Interoceptors are receptors of the visceral afferent pathways, distributed in the walls of visceral glands and vessels. Their terminations include free nerve endings, encapsulated terminals as well as endings associated with specialised epithelial cells.

Exteroceptors and proprioceptors are receptors of somatic afferent pathways, so called somatosensory receptors. Exteroceptors, found at or close to the body surfaces, respond to external stimuli. They are further sub-divided into cutaneous sense organs and special sensory organs, the former comprising free endings and encapsulated terminals in skin and hair, the latter being specialised sensory structures such as gustatory, olfactory, acoustic and visual receptors.

Proprioceptors inform the CNS about the state of the body, responding to stimuli from within. In skeletal muscles such afferent impulses might be regarding their

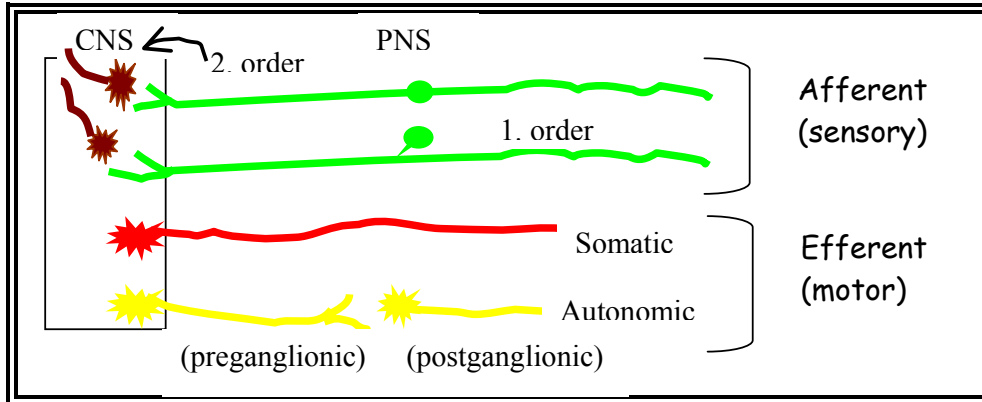


FIG. 3-1 THE AFFERENT AND EFFERENT COMPONENTS OF THE CENTRAL AND PERIPHERAL NERVOUS SYSTEM

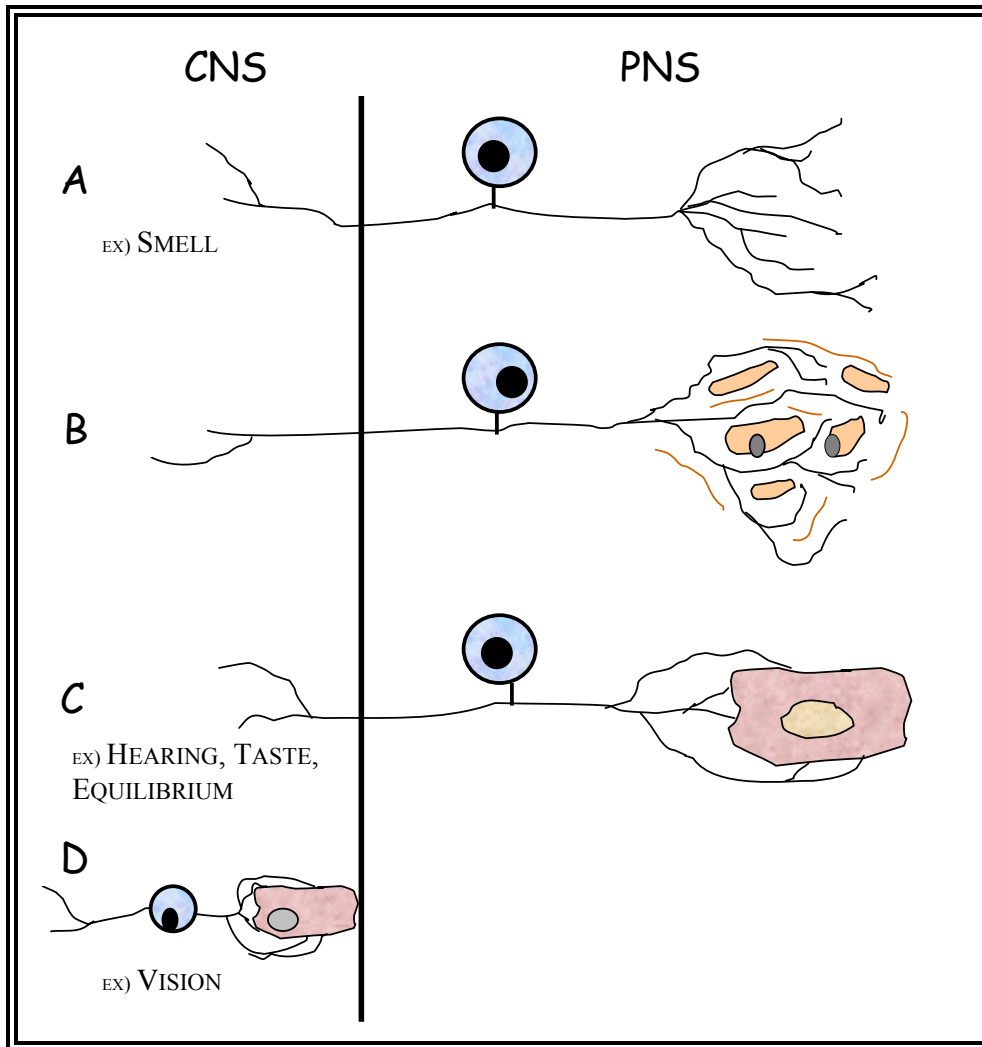


FIG. 3-2 ILLUSTRATION OF HOW RECEPTORS DETECT STIMULI: A) BY THE PERIPHERAL END OF A SENSORY NEURON, B) BY THE PERIPHERAL NERVE ENDING INTERMINGLING AMONG CELLS AND/OR EXTRACELLULAR ELEMENTS, C) BY SPECIAL, OFTEN NON-NEURAL, CELLS DETECTING STIMULI AND THEN ACTIVATING THE PERIPHERAL SENSORY NERVE ENDING. D RESEMBLES C, BUT IS ENTIRELY LOCATED WITHIN THE CNS.

degree of contraction, information that subsequently is integrated with afferent impulses from tendons, ligaments and joint capsules, producing an awareness of body position. This category of receptors includes tendon organs, muscle spindles, Pacinian corpuscles, as well as other endings in joints and vestibular receptors.

Sense organs may alternatively be categorised into three major groups based on their previously mentioned relation to the CNS; neuro-epithelial receptors, epithelial receptors and neuronal receptors. Neuro-epithelial receptors are directly connected to second order neurones in the CNS. They have their somata located peripherally, near the sensory surface, and their axons ending in the CNS. The only example of this type in mammals is the sensory cell of the olfactory epithelium. The receptors of the second group, epithelial receptors, are modified from the cells of a non-nervous sensory epithelium. They are innervated by primary sensory neurones, with their soma situated near the CNS. Examples of these sense organs are gustatory and auditory receptors. Visual receptors are in many ways similar in their form and relations.

The receptors in the third group, neuronal receptors, are primary sensory organs, provided by nerves with soma located in craniospinal ganglions and the peripheral axons endings being the sensory terminals. Cutaneous sensors and proprioceptors, often encapsulated structures, are representatives of the third group.

Furthermore, sensory receptors may also be classified according to the type of stimuli or energy form to which they are especially sensitive: mechanoreceptors, photoreceptors, thermoreceptors, chemoreceptors and osmoreceptors. Mechanoreceptors are sensitive to deformation induced by touch, pressure, sound waves etc. The other receptors are receptive to changes in osmotic pressure.

3.2 *Muscle sense and receptors in the extraocular muscles*

Sensory receptors of muscles are examples of mechanoreceptors. Being disposed in deep rather than surface tissues of the body, they are classified as proprioceptors. They respond to muscle contractions and stretch, tension, movements of joints and changes in body position. Proprioception, a term introduced by Sherrington (1906) for what he claimed was a reflex system based on the afferent signals these receptors initiate, consequently plays an essential role in position sense, coordination of movement, grading of muscular contraction and maintenance of body posture and balance (Ruskell, 1999).

Somatic musculature responsible for minute movements are supplied with a higher frequency and wider complement of such sensory receptors compared to trunk muscles performing larger movements. The unique speed and high precision of eye movements hence suggest a particularly elaborate muscle control system in the extrinsic muscles of the eye.

Vision is a supplementary source of information, unique for the oculorotatory muscles. However, to confidently locate an object in visual space, both the position of the retinal image and of the eye relative to the head needs to be known. The central nervous system hence must receive extraretinal signals regarding eye position and movements as well. The presence of such complementary information has, amongst others, been established in a study by Matin (1986), where eye position sense was proven available even in the absence of vision.

Whether or not afferent signals or “inflow” from proprioceptors in the extraocular muscles and their tendons provides this essential source of information has been a matter of debate for many years. The attributes of proprioception in somatic musculature in providing conscious position sense in addition to regulating posture is not necessarily applicable to EOM. In contrast to trunk muscles, a fixed predictable relationship between muscle contraction and resultant movement is present in the EOMs. The eyeball, which is almost spherical, additionally rotates around its own centre of gravity, resulting in a constant load (Howard, 1982) without gravity influences on the muscle force when moving the eye to different positions in the orbit (Steinbach, 1987). Furthermore, stretch reflexes, generated in somatic muscles, are absent in monkey (Keller and Robinson, 1971), cat (McCouch and Adler, 1932; Baker et al., 1972) and human EOMs (Irvine and Ludvigh, 1937).

Several researchers have consequently excluded “inflow” (the centrally directed information from muscles) as the major contributor to oculomotor control and a different source of signals for the oculomotor control system has therefore been considered. This theory, which originally was introduced by Helmholtz as far back as in 1862, proposes copies of the efferent signals sent to the eye muscle, also termed corollary discharge signals or “outflow”, to provide all information needed for the CNS to specify eye position (Carpenter, 1977; Guthrie et al., 1983). Proprioception from the EOMs is argued unnecessary due to the presence of the highly efficient exteroceptor, the retina, and because of the likely ability of the CNS to monitor efferent outflow from the brainstem. During ocular paralysis, a condition where change in proprioceptive input evidently is lacking, patients experience motion of the visual scene while attempting to move the eye, yet the retinal picture has not been altered (Brindley et al., 1976). Such reports strongly support the theory of efference copy being the potential extraretinal signals taking part in the determination of eye position. The perceptual mislocalizations occur both in unstructured and structured visual field, yet being slightly smaller in the latter (Matin et al., 1982; Bridgeman and Graziano, 1989).

Other studies, investigating subjects without binocular problems, also report findings, which support the importance of efference copy in oculomotor control. Circumstances resulting in approximately corresponding proprioceptive signals, but with a difference in efferent innervation, for instance saccadic eye movements and swift displacements of the eye by finger pressure, give different experiences with regard to apparent movement of the visual scene. Despite shifts in retinal images under both circumstances, movements are only perceived during the latter situation. This is consistent with the theory of Helmholtz, which indicates that the visual scene remains stable merely when there is a balance between retinal image displacement and effort of will to move the eye. The lack of efferent innervation in the latter situation and the resulting movement of the visual scene as a consequence of this imbalance, support the notion that efference copy plays a vital role in oculomotor control and eye position sense. Or otherwise expressed, the experience of a stable visual scene during eye movements is dependent upon efference copy.

It is, nevertheless, still possible that other sensory receptors, for instance located in the retrobulbar fascia, cornea, conjunctiva or other periorbital structures, may be responsible for informing the CNS about the orientation of the eye in the orbit or at least contribute to position sense. However, applying anaesthetics on the anterior ocular surfaces while artificially rotating the eye, give results that support the notion of efference copy as the main contributor to oculomotor control (Irvine and Ludvigh, 1937; Brindley and Merton, 1960; Skavenski, 1972). The anaesthetized subjects report similar movements of the visual scene, yet being totally unaware of having moved the eyes.

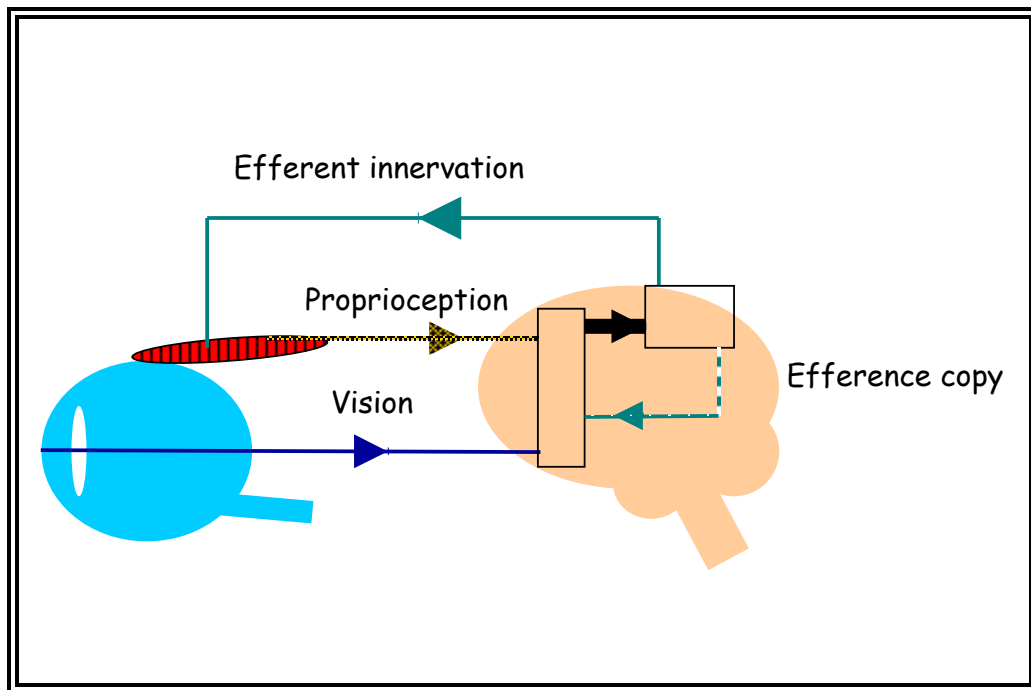


FIG. 3-3 ILLUSTRATION OF THE HYPOTHESIS WHERE VISION, EFFERENCE COPY AS WELL AS PROPRIOCEPTION ARE THOUGHT TO CONOTRIBUTE TO OCULOMOTOR CONTROL

Other scientists support the opinion of Sherrington (1918), who not only introduced the term proprioception but also was the first to propose a perceptual role for extraocular afferent feedback when describing potential receptors in monkey EOMs. As strongly as their opponents argue in favour for efference copy, the supporters of proprioception, based on the numerous studies indicating its

existence, feel confident to claim that “inflow” must contribute to oculomotor control and spatial stability. They emphasize the actual presence of different proprioceptors in the EOMs of various species (Bach-y-Rita and Ito, 1966; Barker, 1974, Maier et al., 1975; Steinbach and Smith, 1981) and the frequently reported signs of afferent signals from the EOMs (Cooper et al., 1955; Donaldson and Long, 1980; Buisseret and Maffei, 1977, Ashton et al., 1988). Hering’s observation of people blind in one eye since birth and yet having apparently perfectly conjugate eye movements as adults, supports this notion of proprioception taking a part in ocular position sense. Maintaining conjugacy is a complicated task for the CNS. The muscles involved have different contractile properties, which again require good feedback so that different amounts of innervation during shifts of fixation in horizontal eye movements may be provided (Meredith and Goldberg, 1986). Fiorentini and Maffei (1977) similarly demonstrate that proprioception supplies some sort of stability signals for fixation since eyes of cats show increased instability in darkness after cutting their proprioceptive pathway in the ophthalmic nerve. Campos and co-workers (1986) demonstrate the role of proprioception in spatial localization in patients with active herpes zoster ophthalmicus, a condition affecting the trigeminal nerve, yet not its efferent division. They measured open-loop pointing responses, and found constant errors of target localization during the active phase of infection. Assuming that proprioceptive afferent signals, as in cats, are conducted through the ophthalmic nerve in humans, this similarly suggests proprioceptively derived information regarding eye position also to be present in humans. Steinbach and Smith (1981) claimed to have found the same results in their study of strabismus operated patients, where myotendinous regions, potentially containing proprioceptors, were surgically manipulated and localization problems occurred. The actual presence of proprioceptors in these areas of adult human EOMs was later confirmed by Richmond et al. (1984). Steinbach and Smith (1981) found the open-loop pointing errors to coincide approximately with the amount of surgical eye rotation, and hence claimed to have found reliable proof of a perceptual role for proprioception.

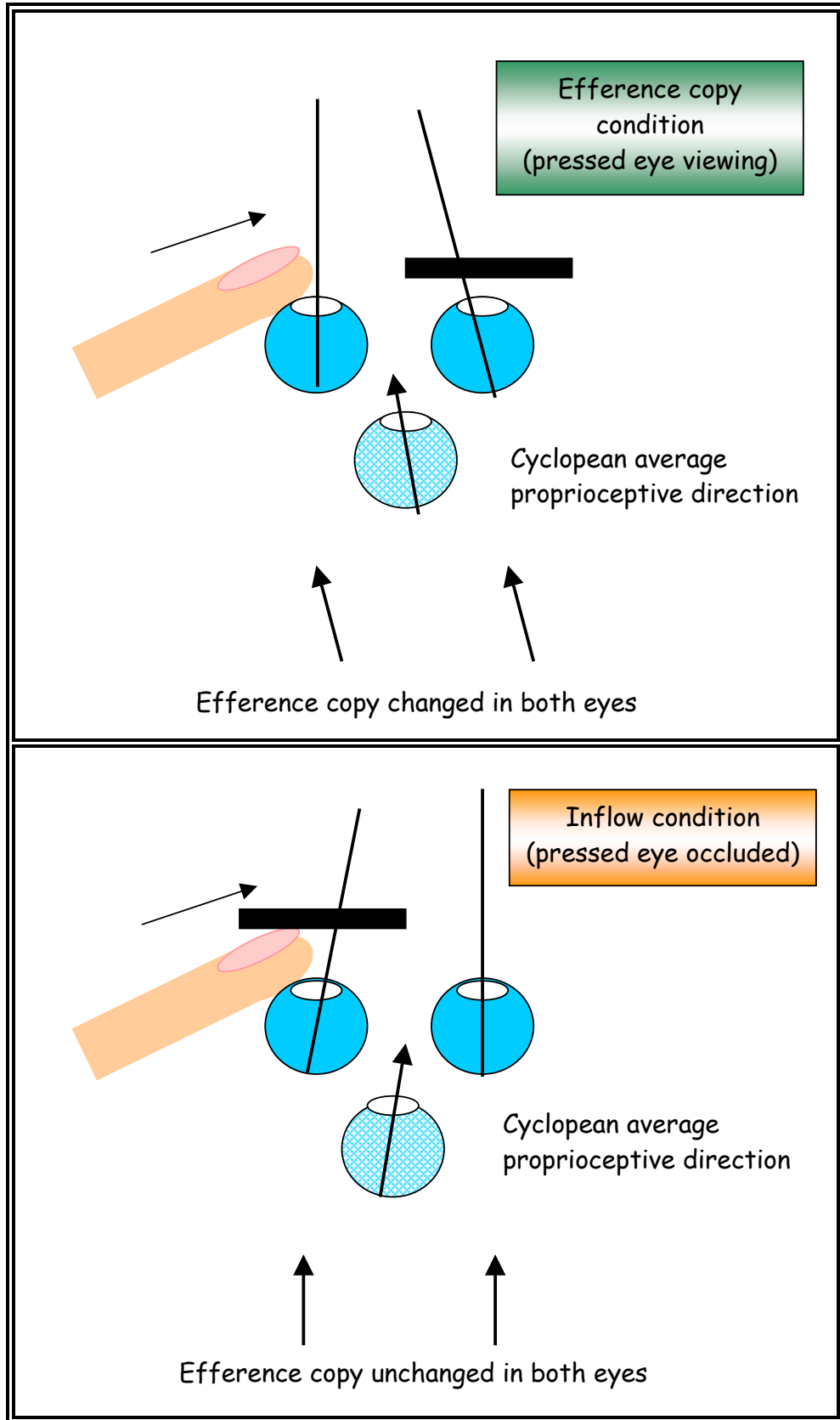


FIG. 3-4 ILLUSTRATION OF THE EYE PRESSURE METHOD APPLIED BY STARK AND BRIDGEMAN (1983)

At this point no studies have been able to produce fully satisfactory evidence, which favours one of the systems against the other. They all have limitations with respect to eliminating all potential sensory elements apart from the one being investigated. The two potential contributors to the oculomotor control system, however, do not necessarily mutually exclude each other. Stark and Bridgeman (1983) showed, by using an eye pressure method, that both systems actually might be collaborating during normal eye movements. When slowly pressing on the side of the eye, while the other eye is occluded, the oculomotor control arrangement stabilizes the system so that fixation is maintained. A mismatch between visual input and efference copy apparently leads to an increase of the efferent innervation to the eye without changing its position. In this situation both eyes get the same increased innervation and as a result, if efference copy was the only contributor to position sense, the resulting movement of the occluded eye should match the perceptual deviation. This is, however, not the case. There is a slight deviation in the results, implicating a dominance of efference copy, yet also a presence of proprioception. After supplementary studies (Bridgeman and Stark, 1991) the same scientists conclude that proprioception, though it provides a significant supplement to the registration of eye position in unstructured visual fields, only function as a back-up system for the principal influence of efferent copy signals. Similar results have also been obtained in other surveys (Optican et al., 1985; Gauthier et al., 1990 and 1995). The relative contributions of the two potential systems in all situations, however, still remain unknown.

During the vehement search to fully understand oculomotor control, proprioception has been proposed to hold alternative roles in the control system. The development of the visual system, metabolic changes, pathological conditions as well as age related degenerations might influence the fixed relationship between muscle contraction and resultant movement (Ludvigh, 1952). Such alterations need to be accounted for, and since increase of muscle activity is seen initiated when the effectiveness of the extraocular muscle is reduced (Optican et al., 1985), calibration of the system has been suggested as a possible task for proprioception (Steinbach, 1986).

It is assumed to be particularly important during the development of binocularity and of the visual system. Gary-Bob et al. (1986) demonstrated that afferent signals from the ophthalmic nerve affected the cortical development in kittens, yet the detailed knowledge of what the signals provide to the development is unclear. Diamond (Hain and Diamond, 1983), who surgically severed the afferent pathway in cats, found visually guided behaviour to be disturbed, but in developing animals only. Graves and co-workers (1987), again using cats, reported results implying ocular proprioception to be necessary in the development of normal depth perception. Ruskell (1989) reported the presence of fragmented, anomalous muscle fibres in adult human muscle spindles, indicating a degeneration of the receptors as a consequence of presumed redundancy. These anomalous muscle fibres were, however, subsequently also revealed in infants (Bruenech and Ruskell, 1993), which decrease their potential value during development of binocular vision in humans.

Proprioception has also been suggested to be vital in the long-term adaptive calibration process related to injuries and pathological ocular conditions (Lewis et al., 1994). While Lewis investigated monkey EOMs, Dengis and co-workers (1998) examined humans with respect to such a role for proprioception. By comparing strabismus patients injected with botulinum toxin with a control group, they found proprioception only to be active during lasting changes. The results from open-loop pointing were the same in both groups in situations with acutely changed eye positions, indicating efference copy to supply the necessary information.

There are further questions regarding the anatomy and physiology of ocular proprioception. The sensory receptors found in skeletal muscles are either absent or present in modified forms in the extrinsic eye muscles of many species. Large variations in the presence, distribution, frequency and complement of proprioceptors occur between species (Maier et al., 1975; Barker, 1974). Variations in the afferent pathway between the various animal groups are also found (Eggers, 1982).

Uncertainties also apply to the alternative concept of efference copy, but some supportive evidence from primates is available (Richmond and Wurtz, 1980).

3.3 *Muscle spindles*

The sensory receptors in extraocular muscles are subdivided according to the same criteria and classification systems as skeletal receptors. There is, however, a larger variation in proprioceptor types, complement and morphology in the extrinsic eye muscles than in somatic cross-striated musculature. The receptors most frequently found, and now to be described, are muscle spindles, Golgi tendon organs and palisade endings or myotendinous cylinders (Ruskell, 1999).

Muscle spindles, mechanoreceptors only found in the musculature of vertebrates, represent one of the most complex sensory receptors in somatic musculature. These important proprioceptors are numerous distributed in connective tissue, lying in parallel with and between bundles of muscle fibres, and thought to have highest density in musculature with high demand for delicate movements and sensory input (Barker, 1974). They are the length-registering receptors of skeletal muscles, signalling the length of the somatic muscle fibres throughout activity and relaxation, as well as the velocity and changes in velocity during contraction. Information conveyed by these proprioceptors is thought to participate in several control mechanisms, including stretch reflexes. Apart from preventing undesirable changes in muscle length caused by changes in the load acting on the muscle, this mechanism helps to maintain balance when involuntary, sudden body movements take place due to displacement of body weight. Underlining their importance even further, the signals also contribute to position and movement sense of the body (Carpenter, 1988).

Seen from a historical point, as described in many papers on sensory receptors (Cooper and Daniel, 1949; Sas and Appeltauer, 1963; Barker, 1974), Weissmann (1861), while investigating teased frog skeletal muscles, was the first to recognise the muscle spindle as a discrete entity. He suggested them to be ordinary muscle fibres splitting up to form additional fibres. Kühne (1863), on the other hand, was

the first to imply these spindles to have some sort of physiological function for the muscle contraction. His theory, however, was long ignored but his term «Muskelspindeln», which was referring to its fusiform shape, was rapidly adopted.

Many suggestions on its nature were made in the subsequent studies, such as pathological formations, centres of muscle regeneration and even parasites. Only a few decades later, however, the muscle spindles were finally accepted as sense organs due to the existing similarities between the spindle and the encapsulated tendon organ, which had been discovered by Golgi in 1880. The sensory nature of the tendon organ was yet still to be proven, but it was generally believed that Golgi was correct in assuming that it was a receptor recording muscle tension, and hence the spindles were surmised to have a proprioceptive function as well. Kerschner and Ruffini, around 1890, supported this hypothesis. They were convinced by the complex form and nature of the nerves innervating the intracapsular muscle fibres, which they, moreover, were the first to describe in any detail in mammals.

Sherrington, in 1894, assembled the necessary proof for their sensory nature by finding them to remain intact in cat and monkey musculature after cutting the ventral neural roots. Through his work he also introduced the term «equatorial region» for the widest and fluid-filled part of the receptor that holds the area of sensory innervation. He distinguished between this area and the «polar region» of the muscle fibres, which extend to each side within the receptor.

Not only do ocular muscle spindles show morphological variations between species (Barker, 1974; Ruskell, 1989), they also slightly differ from conventional, skeletal muscle spindles (Buzzard, 1908, Maier et al., 1975). The structure of the latter is, nonetheless, still highly applicable as a model when describing the former.

Apart from some smaller differences between species, most conventional muscle spindles show rather identical features. The elongated spindle-shaped receptors have a diameter of about 0.2 mm at their widest portion in man, a length of about 1-5 mm (Brodal, 1990) and are almost entirely enclosed by an external capsule of connective tissue. The cells composing the capsule are thin, flat perineural cells, a continuation of the perineurium of the nerve innervating the receptor. They are arranged in a concentric tubular fashion, alternating with layers filled with collagen

fibres, giving the capsule a laminated appearance. The number of layers varies slightly, both between spindles in the same muscle and between different muscles. Nerve fibres, in company with capillaries, occasionally course for long distances between these lamellae.

At the equatorial region the spindle expands its diameter to give space for intracapsular fluid, which together with the capsule serves as a shock absorber, protecting the spindle from being stimulated by lateral pressure exerted by muscle contraction (Brzezinski, 1961). The periaxial space is continuous with the subperineural space surrounding the supplying nerve trunk, which again implies an ultimate communication with the subpial space surrounding the spinal cord. Since all these spaces are fluid-filled, it is reasonable to assume that both the central and peripheral nervous system are enclosed within a fluid-filled envelope of epithelial cells, part of which forms the capsule and the periaxial space of the spindle (Barker, 1974).

Rather short, thin and uniquely formed muscle fibres, 4-12 in number, are suspended within the capsule and course through the receptor along its axis. To distinguish them from the thicker muscle fibres outside the spindle, the extrafusal fibres, these fibres are termed intrafusal muscle fibres. A thin sheet of connective tissue invests the intrafusal fibres in the equatorial region, forming an inner capsule named the axial sheet of Sherrington. Supporting strands of trabecular tissue protrude from this sheet and traverse the periaxial space to fuse with the external capsule wall where it is at its thickest.

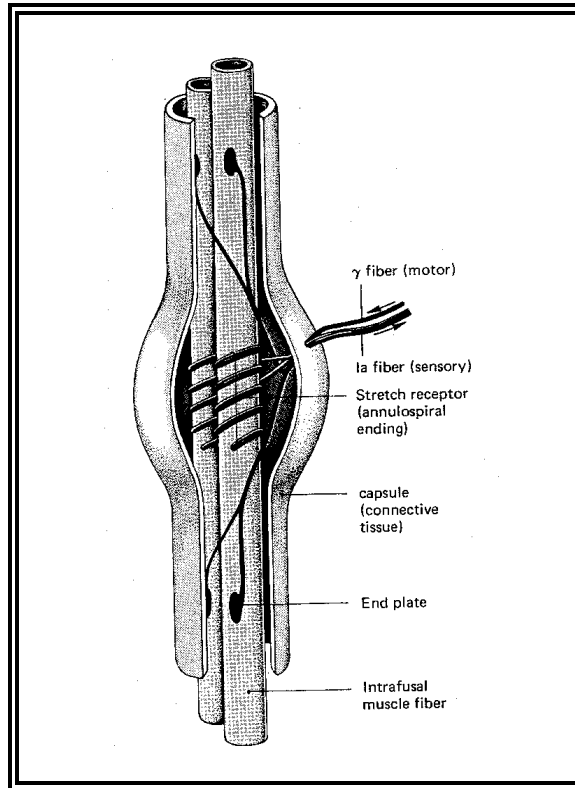


FIG. 3-5 MUSCLE SPINDLE (FUNDAMENTALS OF NEUROPHYSIOLOGY 2.ED, SCHMIDT)

The majority of the periaxial space is confined to the expanded receptor zone, which usually occupies the middle third of the spindle length. Only a very narrow extension of the intracapsular lumen continues for some length along each polar region, but these prolongations are so thin that electron microscopy is required for detection. At each pole the capsule thins down, forms a collar, which closes the intracapsular lumen, for then to finally disappear. The number of intrafusal muscle fibres decreases, and the ones remaining tend to spread out and pursue individual courses to intramuscular connective tissue, tendon, or extrafusal endomysium. Two different types of intrafusal muscle fibres may be distinguished microscopically; nuclear chain fibres and nuclear bag fibres, the latter being slightly longer and thicker than the former (Cooper et al., 1955). Both fibre types have been reported in several mammalian skeletal spindles, usually with the nuclear chain fibres outnumbering the bag fibres. Within the equatorial region all fibres, regardless of type, become modified. They undergo a marked increment in nucleation and almost a total drop in contractile elements. The nuclear bag fibres

here possess a short region with accumulated round nuclei, over 50-100 in number depending on the length of the bag, which tapers off on either side into a row of elongated nuclei within the central core of sarcoplasm. The nuclear chain fibres reduce their diameter to a little more than that of each nucleus and their lenticular nuclei, about 20-50 in number, are displaced from a peripheral to a central location to form an equatorial chain. Bag nuclei in sheep spindles are 6-9 μm in diameter, the chain nuclei 9-12 μm long and 6 μm wide.

The bag fibres often extend well beyond the limits of the capsule. In certain species some of the chain fibres extend beyond the limits of the capsule as well. The majority are, however, attached to the inner wall at the poles or form strong lateral attachments to it before emerging for a short distance.

The intrafusal fibres are unique not only in respect of size and nucleation, but also through their polyneuronal supply by sensory as well as motor fibres. They receive their sensory innervation in the equatorial region, and the length of the periaxial space and capsule vary according to the number of sensory endings present. Thick myelinated axons, primary afferents described as group Ia, terminate as unmyelinated annulospiral endings on the modified region of both fibre types in most mammals (Barker, 1974). Nuclear chain fibres receive an additional secondary sensory innervation from finer fibres, described as group II, which terminate as non-myelinated flower-spray and annulospiral endings on each side of the primary ending. Primary endings respond to both degree and rate of stretch of a muscle, while secondary endings respond to degree of stretch only.

Myelinated, fine efferent axons innervate both fibre types and terminate on their contractile polar regions (Sas and Appeltauer, 1963). Thin, unmyelinated autonomic nerves, related to blood vessels, are also found.

The purpose of the efferent innervation of the intrafusal muscle fibres is not to provide further contractile force for the muscle as a whole, but to regulate the sensitivity of the spindles to stretch. This motor innervation is composed of small fibres from gamma (γ) motoneurons, a term introduced by Leksell (1945) to distinguish them from the larger alpha (α) motor nerves endings on extrafusal fibres. A muscle spindle response is initiated by stretch of its afferent endings.

An α innervation of the extrafusal fibres will create an offload of the intrafusal fibres. γ efferent impulses elicit contraction of the intrafusal fibres in their polar areas. By co activating α and γ efferent nerves the contraction of the intrafusal fibres compensate for the α induced offload. The γ impulses hence function as a sensitivity regulating mechanism, preparing the receptor to respond to stretch regardless of muscle length.

3.4 *Muscle spindles in extraocular muscles*

Extraocular muscles are often described as musculature performing fine graded movements, with a high need of sensory input and abundant supply of muscle spindles. This is, however, rather misleading. Not only are there confusingly large variations in receptor distribution between species (Harker, 1972; Barker, 1974; Maier et al., 1975), some spindles in extrinsic eye musculature also show structural departure from the conventional receptors (Cooper and Daniel, 1949; Ruskell, 1989, Bruenech and Ruskell, 1993, Bruenech and Ruskell, 2001). Certain animal groups possess few, if any muscle spindles, whilst others have a generous supply. Similar inconsistencies even occur between animals of the same species. Currently, spindles have been described in the EOMs of man, chimpanzee, mouse, sheep, goat, cow, ox, pig, deer, giraffe, wild boar and gnu. None have been found in cat, rat, rabbit, macaque monkey, dog, hare, fox, baboon, cheetah and birds (Cooper and Daniel, 1949; Greene and Jampel, 1966; Harker, 1972; Barker, 1974; Ruskell and Wilson, 1983; Maier et al, 1975; Billig et al., 1997). With regard to structural peculiarities, nuclear bag fibres are present in very low numbers in human ocular receptors (Ruskell, 1989), while both types of intrafusal fibres are present in ocular muscle spindles of sheep (Ruskell, 1979). Anomalous fibres, a term introduced by Ruskell for intrafusal muscle fibres lacking equatorial nucleation, are other peculiar features present in human adults as well as infants (Ruskell, 1989; Bruenech and Ruskell, 1993; Blumer et al, 1998).

No obvious explanations have yet been found for these distributional variations and structural peculiarities. Long lasting debates regarding their potential functional role in oculomotor control and numerous investigations have been initiated due to the irregularities. Conclusive results, however, revealing the full nature of the story remain to be revealed.

According to receptor related literature (Cooper et al., 1955; Ruskell, 1999) the presence of muscle spindles in human EOMs was mentioned for the first time in 1888 by Siemmerling. Buzzard (1908) was, however, the first to describe and illustrate them with micrographs. A few years later, 1910, they were also found in the EOMs of several other mammals. Through this extensive study of non-primate species, Cilimbaris (1910) was able to present the first detailed structural description of the receptor. Their regular presence in human EOMs was, however, not wholly accepted until they were re-described in detail by Cooper and Daniel (1949). Merrillees et al. (1950), who confirmed the findings, revealed the receptors to be present in a surprisingly high number, as many as 71 being found in one single human EOM. Most of these spindles were seen in the proximal and distal third of the muscle, away from the motor end-plate zone in the middle region, and in the muscle periphery.

However, using encapsulation alone as a criterion for identifying muscle spindles is now known to be inadequate as groups of extrafusal fibres are sometimes briefly enclosed by a capsule, forming so-called false spindles (Ruskell, 1984).

Their presence partly accounts for the lower number of spindles per muscle, from 2 to 34, that has been reported more recently in human EOMs by other authors (Lukas et al., 1994; Bruenech and Ruskell, 2001).

Spiral nerve endings, described for the first time by Dogiel (1906), might have caused a similar confusion in evaluating muscle spindle distribution. These structures, resembling Kühne's spindle (1864), are muscle fibres, mostly encapsulated, with a complicated spiral nerve ending. They have been assumed to be of sensory origin (Daniel, 1946; Barker, 1974), until Ruskell and Wilson (1983), Ruskell (1984) and Billig et al. (1997) in their study of monkey, man and cat respectively, proved them to be efferent nerve fibres. Ruskell (1984) described

them as myelinated efferent nerve endings which wrap around extrafusal muscle fibres, making three to eight complete turns around a muscle fibre of any size, with small clusters of terminal boutons occurring at intervals along the fibre.

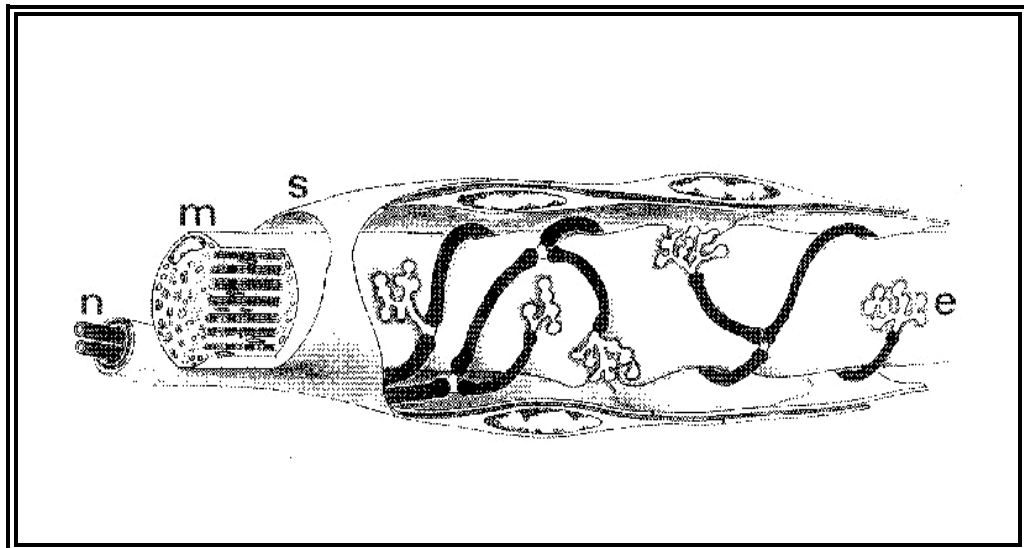


FIG. 3-6 HUMAN SPIRAL NERVE ENDING (RUSKELL, 1999). "N" REPRESENTS MOTOR NERVE, "M" MUSCLE FIBRE, "S" SHEATH AND "E" NERVE ENDING.

The extraocular muscle spindles of sheep are in most respects of standard skeletal spindle form (Ruskell, 1989). The human ocular spindles, in contrast, show several atypical features (Buzzard, 1908; Sas and Appeltauer, 1963; Ruskell, 1989). They are smaller and more delicate than their counterparts in somatic muscles (Maier et al., 1975). The periaxial space is very reduced (Sas and Appeltauer, 1963) and the equatorial region ill defined, giving the extraocular receptor a more cylindrical appearance rather than a fusiform shape (Ruskell, 1989). The equatorial diameter varies from 10 to 182 μm and they have a length from 47 up to 1640 μm (Cooper and Daniel, 1949, Merrillees et al., 1950; Sas and Appeltauer, 1963; Ruskell, 1989, Bruenech and Ruskell, 2001). The longest receptors tend to have the widest equatorial region.

The thin capsule, containing 2 to 4 laminae of fibrous tissue, occasionally splits to include an extrafusal muscle fibre. A complete inner capsule is usually not present,

but many muscle fibres are invested by rather disorganised strands of connective tissue cells, which again make contact with the outer capsule.

Between 1 and 18 intrafusal muscle fibres occupy human ocular spindles (Ruskell, 1989; Lukas et al., 1997, Bruenech and Ruskell, 2001). The numbers, which appear to be unrelated to spindle length, compare relatively well with those of the conventional spindles. In contrast, the fibres show a larger variation in their diameters (Cooper and Daniel, 1949), many of them even being comparable with surrounding extrafusal fibre size (Buzzard, 1908; Cooper and Daniel, 1949; Merrillees et al., 1950; Lukas et al., 1997). The spindles located in muscle areas with small extrafusal fibres tend to have small intrafusal fibres, and vice versa (Ruskell, 1989; Bruenech and Ruskell, 2001).

Very few of the human intrafusal fibres show an accumulation of nuclei which would identify them as nuclear bag fibres. A larger proportion of the muscle fibres are of nuclear chain type (Sas and Appeltauer, 1963; Ruskell, 1989; Lukas et al., 1997; Bruenech and Ruskell, 2001); the remainder are either bag fibres, having two or three nuclei lying abreast in the myotube region, or so-called anomalous fibres (Ruskell, 1989; Lukas et al., 1997).

Human nuclear chain fibres have centrally placed nuclei in the myotube region and sometimes along the whole length of the intrafusal fibre, with little contractile elements throughout. No motor end plates are distinguished in the polar areas (Sas and Appeltauer, 1963), their sensory regions are almost always out of register and the majority of the nuclear chain fibres in adults and infants are fragmented (Ruskell, 1989; Blumer et al., 1998; Ruskell, 1999; Bruenech and Ruskell, 2001).

Anomalous fibres occur exclusively in human extraocular muscles. They enter the spindles at the poles, have peripherally located nuclei, no equatorial modification, and myofilamentous material occupies the entire fibre length (Ruskell, 1989; Bruenech and Ruskell, 2001). The fibres often fail to run the full length of the spindle. Lukas and co-workers (1997) claimed all of them, like other intrafusal fibres, to be richly innervated by primary sensory endings. Ruskell (1989), on the other hand, found only 7 % to have a supply of sensory nerve fibres while Blumer

fibres, to be richly innervated by primary sensory endings. Ruskell (1989), on the other hand, found only 7 % to have a supply of sensory nerve fibres while Blumer et al. (1998) reported none. Motor terminals were, however, present in the polar areas.

These chain fibres, anomalous muscle fibres and fragmented fibres are amongst the peculiarities of human extrinsic eye spindles which have generated questions about their ability to function as proprioceptors (Harker, 1972; Ruskell, 1989; Ruskell, 1999). Based on these features human ocular spindles have been suggested to be phylogenetically redundant (Ruskell, 1989). Their additional lack of protection against environmental disturbances has been found to strengthen the notion even further. Limited axial space and a consequential lack of buffer against external influences, such as contraction of local extrafusar fibres, are implied to affect the function normally attributed to spindles. A simultaneous contraction of the unmodified muscle fibres within the spindle would also abnormally excite the sensory endings.

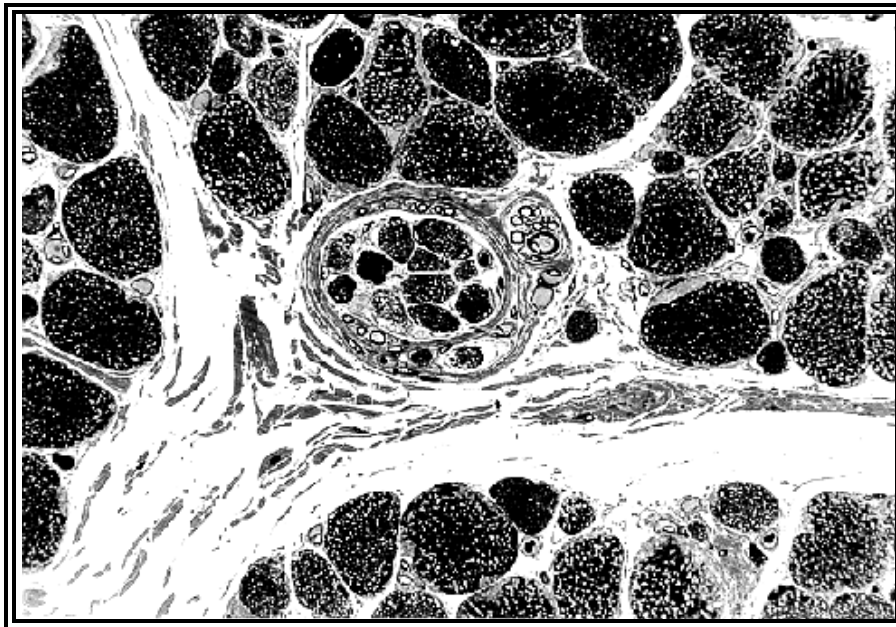


FIG. 3-7 MICROGRAPH OF A MUSCLE SPINDLE IN SHEEP EOM, LM/TS, STAINED WITH TOLUIDINE BLUE

Muscle spindles are distributed with a much higher frequency in the oculorotatory muscles of artiodactyls; 148 and 181 have been reported in single EOMs of sheep by Cilimbaris (1910) and Harker (1972) respectively. Levator palpebrae superioris have between 23 and 61 spindles distributed throughout the muscle (Cilimbaris,

1910; Harker, 1972). Most spindles are found in the periphery of the rotatory muscles, while they are randomly distributed in LPSs. Some of them appear in closely connected groups, so called compound spindles (Barker, 1974).

In contrast to the human receptors, the spindles in sheep have a structure that conforms to that of skeletal muscle spindles (Ruskell, 1989). From 2 to 16 standard intrafusal muscle fibres are present, chain fibres outnumbering the bag fibres (Harker, 1972; Ruskell, 1989). They show a continuous range of fibre diameters, the nuclear bag fibres generally being larger. All fibres are substantially smaller in diameter than the surrounding extrafusal fibres, in average 12 μm versus 21 μm , and their motor innervation compares with that of somatic muscle spindles (Harker, 1972; Ruskell, 1989). All sensory regions are in register.

An inner capsule surrounds the bundles of muscle fibres, which are centrally placed within the capsular lumen. The spindles show the conventional wide equatorial expansion, with a diameter varying between 95 to 175 μm . The intracapsular lumen is abundantly filled with fluid (Ruskell, 1989), which separates the inner and outer capsules.

The investigations of monkey and ape EOMs have revealed less consistent results. Yet discharges in fibres of the peripheral oculorotatory nerves have been registered in response to stretching EOMs, indicating a potential presence of stretch receptors in monkey (Cooper and Fillenz, 1955); some researchers were unable to find any spindles in this species (Sherrington, 1893; Cooper and Daniel, 1949). Others have, however, discovered a few (Cooper et al., 1955; Greene and Jampel, 1966; Maier et al., 1975). These spindles resembled human spindles by being smaller than conventional spindles, not possessing a clear equatorial expansion and, in some instances, seemingly lacking enclosed nerves. Similar inconsistent results were obtained with regard to the larger primates, baboons and chimpanzees. Some scientists have found a few of these spindles in certain EOMs of baboons, whilst others found none (Maier et al., 1975; Durston, 1974). Cooper and Daniel (1949) similarly discovered a few receptors in chimpanzees.

3.5 Golgi tendon organs

Tendon of somatic musculature holds several kinds of sensory nerve endings, some being more complex than others. The terminals are either simple, naked branches of axons spreading amongst the tendon fibrils in various treelike figures or relatively complicated forms of encapsulated structures, the Golgi tendon organ (GTO) being by far the most common.

Golgi tendon organs are slightly less complex than muscle spindles. They are found in a majority of muscles containing muscle spindles and are regarded to be a part of the standard proprioceptive equipment in mammalian striated somatic musculature.

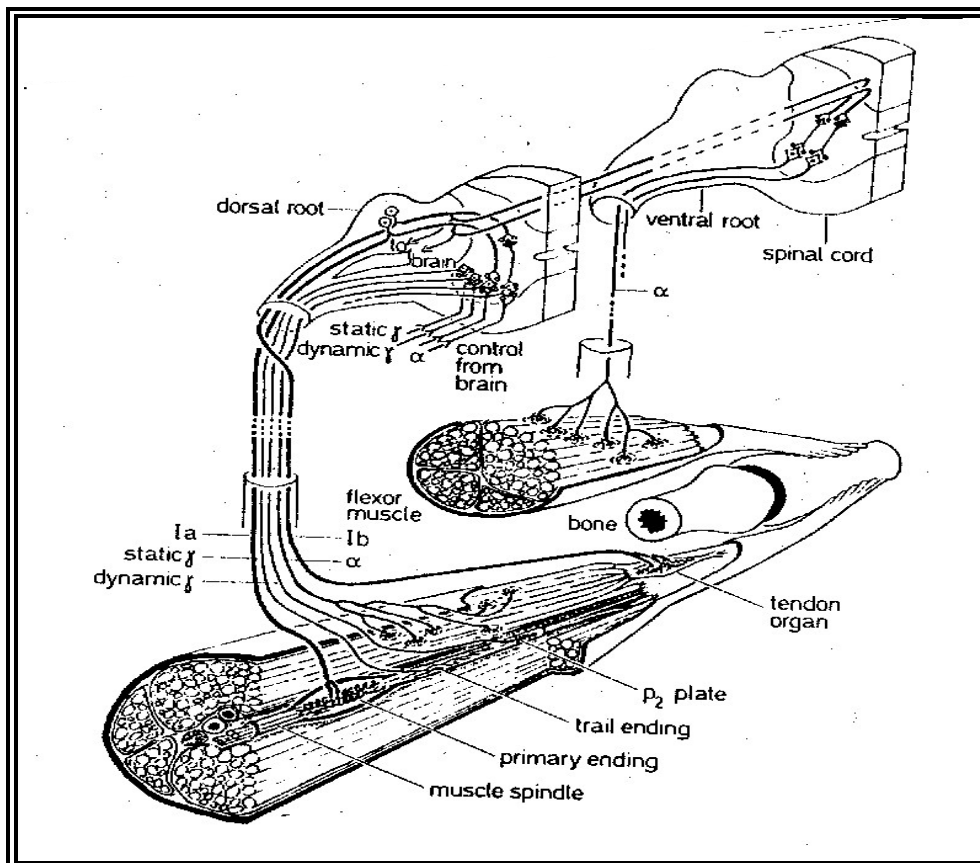


FIG. 3-8 SCHEMATIC DIAGRAM OF THE LOCATION AND INNERVATION OF MUSCLE SPINDLE AND GOLGI TENDON ORGAN IN CAT SKELETAL MUSCLE (BARKER, 1974)

The tendon organs are most frequently observed at the musculo-tendinous junctions, although some of them occasionally occur in intramuscular junctions or centrally within pure tendon as well (Bridgeman, 1968; Schoultz and Swett, 1972). They lie in series with the muscle fibres, usually attached to a small group of muscle fibres at one pole, and connected to an aponeurosis or tendon at the other. The proprioceptors are slowly adapting receptors, sensitive to mechanical forces exerted at the musculo-tendinous boundaries during passive stretch or active contraction (Houk and Henneman, 1967). Muscle spindles contribute to the regulation of motor activity by initiating reflex contractions of the muscle when being stretched. GTOs participate in the same regulation of muscle activity, but through an inverse stretch reflex circuit, which initiates a relaxation of the muscle when being stretched over a certain length. The latter receptor thus functions as a muscle force regulator whilst muscle spindles regulate muscle length. For many years the GTOs have generally been defined as high threshold receptors due to their slow response to mechanical stretch. The elasticity of the muscle fibres, which take up much of the stretch during passive lengthening, was thought to partially explain the need of a strong stimulation for the receptor to respond. Scientists now also find them to be low threshold receptors when responding to tension generated by normally contracting muscle fibres (Jami, 1992).

According to the literature (Barker, 1974; Hunt, 1974; Zelena and Soukup, 1977; Ruskell, 1999), GTOs were described for the first time by Golgi in 1880. He discovered them in a broad range of animals and called them musculo-tendinous organs because he found one end of the tendon organ always to be muscular and the other tendinous. Eight years later Cattaneo (1888) established the sensory nature of the terminals by showing that tendon organ and its innervation remained intact after cutting the ventral roots of the nerves supplying the somatic muscle. Huber and De Witt (1900) were the first to present comprehensive information regarding the morphology of the GTO.

Further knowledge about structure, innervation and distribution of the tendon organs in various species have successively been provided throughout the following

decades. The minute structure of tendon receptors was, however, not fully exposed until 1962 when Merrillees, in his EM study of rat GTOs, revealed a close interrelation between the sensory nerve terminals and the collagen bundles that occupies the receptor lumen. Several studies have been undertaken since then and the various ultrastructural features even more thoroughly described (Schoultz and Swett, 1972, 1973).

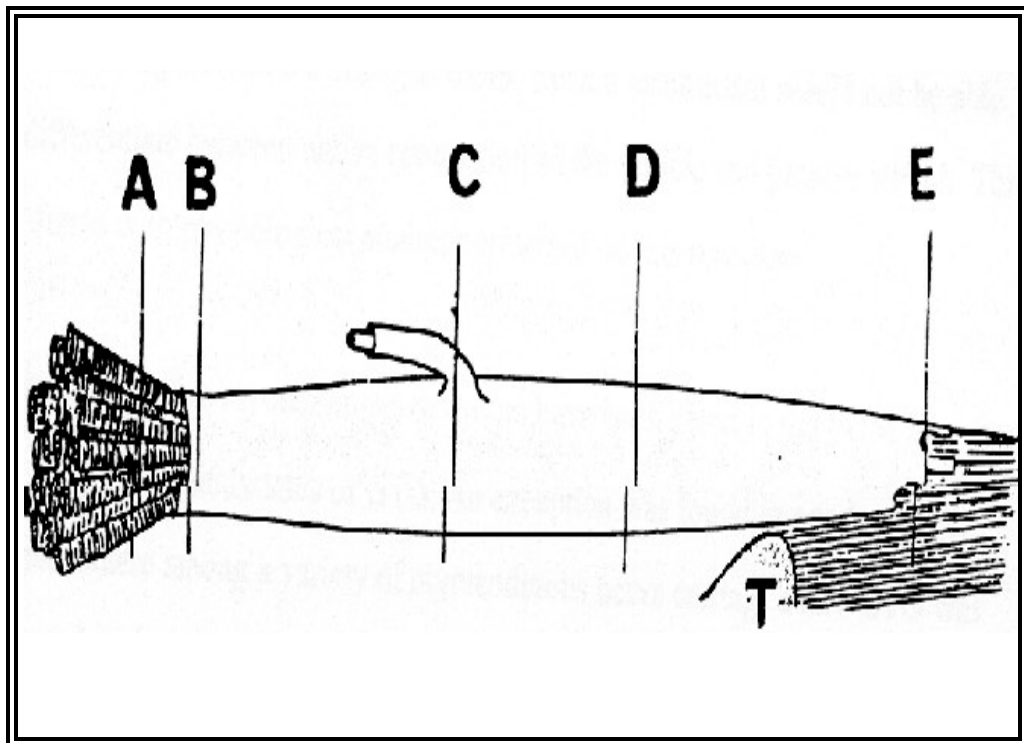


FIG. 3-9 GOLGI TENDON ORGAN (SCHOULTZ AND SWETT, 1972) . "A" REPRESENTING THE MUSCLE FIBRE TO WHICH THE GTO IS ATTACHED, "B" THE MUSCULAR POLE, "C" THE ENTRY OF THE SENSORY NERVE, "D" THE WIDEST PART OF THE CAPSULE , "E" THE TENDINOUS POLE AND "T" THE TENDON.

Tendon organs in somatic musculature are generally described as encapsulated bundles of small tendon fascicles innervated by a large myelinated afferent nerve. They have an elongated fusiform shape and like muscle spindles, their presence and dimensions vary between muscles as well as between species. Skeletal GTOs of rat are approximately 650 μm long, with a maximal diameter of 50 μm (Bridgeman, , 1970). Tendon organs in cats have an average length of 500 μm and measure 100 μm across the widest part, but both thinner and longer, up to 1100 μm ,

receptors have been reported (Bridgeman, 1970; Schoultz and Swett, 1972, 1973; Barker, 1974). The encapsulated tendon is generally attached to 3-4 muscle fibres, but this structural feature also varies between species. Bridgeman (1970) found the GTOs of rat to be formed by tendinous fascicles of 5-6 muscle fibres, cat GTOs up to 25, while human GTOs connected to 10-20 muscle fibres.

The capsules of tendon receptors are less developed than their counterparts in muscle spindles. It is composed of several thin layers of concentric, highly attenuated, overlapping capsule cells, separated by interlamellar spaces of varying width, which contain collagen fibrils and small scattered bundles of microfibrils. Most of the collagen fibrils are of smaller diameter than those of the central muscle tendon and run in parallel with the long axis of the capsule. Oblique and circumferentially orientated bands of collagen do, however, occasionally occur. The capsule covers the receptor from pole to pole. As in muscle spindles, its cells share the morphological features of perineural epithelial cells, hence being a direct continuation of the perineural sheath surrounding the supplying nerve (Schoultz and Swett, 1973; Barker, 1974).

At the poles the capsule constricts to form tight fitting collars around the bundles of collagen. The tightness of the collars produces an effective seal for the intracapsular fluid. The muscle fibres converge sharply as they approach the proximal capsule opening, but they never seem to enter the capsular lumen. In their course beyond this point all muscle fibres are replaced by collagen fibrils, which subsequently emerge from the intracapsular lumen at the opposite pole to blend with the central tendon of the muscle. The collagen bundles within the receptor are smaller and not as tightly packed as those forming ordinary tendon.

In the polar areas the capsule is prolonged into septa, which divide the bundles into longitudinal compartments. In these regions the collagen fibrils are relatively densely packed, but as they course through the receptor they get more loosely bundled. The compartments successively become irregularly shaped as more and more fluid-filled spaces separate the collagen bundles. At this level other attenuated

cells, incompletely surrounding the compartments, replace the capsule cell extensions. These equatorial septa are made of cellular elements distinctly different from capsule cell extensions with extremely thin and long fibrocyte processes.

The septa at the proximal pole encircle collagen fibres from a distinct set of muscle fibres. The various compartments in the mid-region of the receptor are, however, not necessarily associated with the same groups of collagen fibres as they were at the pole. In this vicinity the compartments subdivide and then rejoin and frequently incorporate collagen fibres from other bundles. The fascicles in the mid-region are generally smaller and more numerous than those at either end (Bridgeman, 1968). The number of collagen fibres emerging from the distal capsule opening is, nonetheless, roughly half the number entering at the proximal pole.

The receptor wall is more or less uninterrupted apart from the site where nerve fibres and blood vessels penetrate the capsule to supply the GTO. At this point, about midway along the receptor length, the perineural sheath of the nerve fibres becomes continuous with the outer lamellae of the capsule and the subperineural fluid and the intracapsular fluid intermix (Steer and Horney, 1968; Schoultz and Swett, 1973). The small blood vessels approaching the GTO alongside the nerve are rarely seen entering the intracapsular lumen. They supply the capillary branches of the capsule wall, which run between the laminae, perpendicular to the axis of the receptor. These branches subsequently drain into a venule on the opposite side of the receptor, which again usually is orientated parallel to the receptor axis.

The nerve fibres supplying the GTOs are derived from intramuscular nerve trunks. The majority of the axons are large and myelinated, originating from primary afferent Ib nerves or their myelinated branches (Barker, 1962). The remaining fibres are small and unmyelinated, assumed to innervate the smooth muscle fibres in the vascular walls. Other efferent innervation is not present in these receptors. Whilst the latter nerve fibres never seem to enter the GTO lumen, the afferent Ib fibres ultimately ramifies and have their terminals widely spread amongst the spiralling compartments of collagen within the receptor body.

Both myelinated and unmyelinated Ib axons are found in the various intracapsular compartments, but unmyelinated terminals are only seen amongst and in close contact with loosely organised collagen fibrils (Schoultz and Swett, 1973). The large Ib nerve divides into two main branches just prior to or after entering the equatorial region of the GTO. When having reached a central position within the lumen, the branches subdivide even further and take opposite longitudinal courses to provide innervation to both receptor halves. As they advance within centrally located compartments, usually devoid of collagen, they divide repetitively and finally give rise to small unmyelinated branches. At this point the unmyelinated fibres are still invested by Schwann cell processes and basal lamina, but as the small collaterals project radially to take a sinuous course between and around the loosely organised collagen bundles in the surrounding compartments, they become uncovered terminal axons. The small terminal branches possess numerous irregular varicosities providing large terminal surfaces. They ultimately terminate in a number of arborisation, encircling and attaching to the small, subdivided collagen fascicles in an irregular fashion. Such terminals are found at most levels within the receptor body, none, however, occur in the densely packed compartments of the poles. The Schwann cells, covering all the primary afferent fibre except the most distal parts of the terminals, are distinguishable from septal cells by the presence a basal lamina and by their larger and rounder profiles of the nuclei.

In the early stages of GTO development contacts are made between nerve terminals and muscle fibres. As the receptors mature after birth the fibres withdraw from the encapsulated receptor and neuromuscular contacts are lost (Zelena and Soukup, 1977).

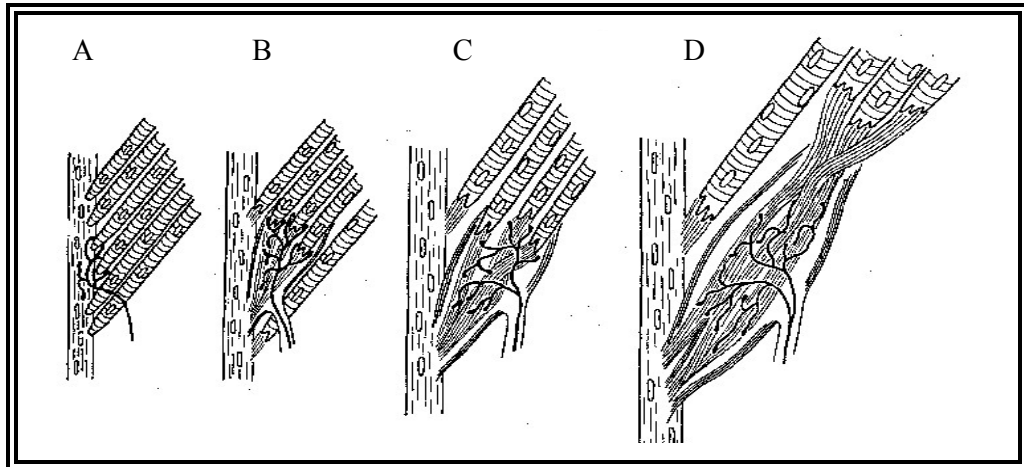


FIG. 3-10 DEVELOPMENT OF GTOs IN RAT SKELETAL MUSCLE (ZELENA AND SOUKUP, 1977). "A" REPRESENTS DAY 21 GESTATION, "B" 3 DAYS AFTER BIRTH, "C" 5 DAYS AFTER BIRTH AND "D" 14 DAYS AFTER BIRTH.

Several suggestions have been made with regard to the response mechanism of the GTO. A mechanical deformation of the sensory terminals, which again propagate an action potential, seems currently to be the most applied surmise. Muscle contraction or passive elongation stretches the collagen bundles and because of the close entwined arrangement between collagen and axon terminals, the latter are likely to get squeezed and distorted concurrently (Merrillees, 1962; Bridgeman, 1968; Swett and Schoultz, 1972). Increased tensile force on the collagen in the GTO hence, dependent upon the intensity and duration of the mechanical stimulus; induces action potentials (Hunt 1974).

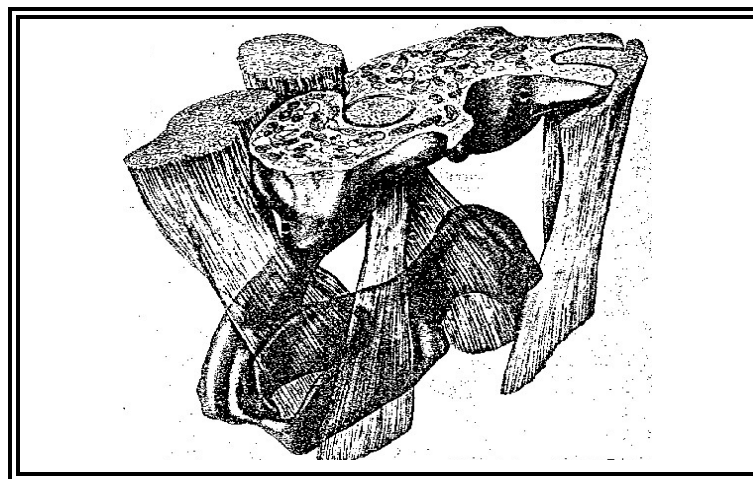


FIG. 3-11 THE CLOSE RELATIONSHIP BETWEEN COLLAGEN AND NERVE ENDINGS WITHIN A GTO (SCHOULTZ AND SWETT, 1972). THE ARROW POINTING TOWARDS THE NEURAL TISSUE.

Muscle spindles and tendon organs are occasionally located very close to each other. The intrafusal muscle fibres of a muscle spindle some times attach to the end of a GTO, linking them together. More frequently, however, the two types of proprioceptors are found alongside each other in a juxtaposition referred to as spindle-tendon organ dyad (Marchand et al., 1971). Tendon organs in such dyads in cat tend to be larger than the solitary ones (Barker, 1974). Paciniform terminals have also been described among the GTO population.

3.6 *Golgi tendon organs in extraocular muscles*

Golgi described tendon organs in skeletal muscles, but overlooked their presence in ocular musculature. Marchi (1882) was hence the first to find such neurotendinous afferent endings in EOMs and he also exposed them in a wide variety of species. A few years later, in 1891, Ciaccio produced the first detailed illustrations (Ruskell, 1999). Several studies of EOMs have subsequently been undertaken during the following century and the presence of receptors in extraocular tendons of various species confirmed (Huber, 1900; Dogiel, 1906; Cooper and Daniel, 1949; Bonavolunta, 1956; Ruskell, 1990; Blumer et al., 2000; Kjellevoid Haugen, 2001).

Ocular tendon receptors often show structural features which contrast to those of conventional GTOs. Large variations in morphology and distribution between species as well as between individual animals occur (Ruskell, 1978; Alvarado-Mallart and Pinçon-Raymond, 1979; Ruskell, 1990). A classification system exclusive for EOM tendon receptors has been suggested and a subdivision into two main groups is now commonly acknowledged - Golgi tendon organs and palisade endings/myotendinous cylinders (Ruskell, 1978; Alvarado-Mallart and Pinçon-Raymond, 1979; Ruskell, 1990). Descriptions of the latter ocular structures will be given separately. In this section attention will be restricted to those structures either explicitly of GTO form or closely resembling them.

Golgi tendon organs are not frequently observed in EOMs. They are absent in the distal extraocular tendons of cat and man (Richmond et al., 1984; Sodi et al., 1988), and occur rarely in the distal tendon of monkeys (Ruskell, 1979). Proximal GTOs had not been exposed in any species, until the recent work on sheep EOMs by Ruskell in 1990, where they were found abundantly distributed. The reason for this is probably neglect of the proximal tendon as a possible site for tendon receptors, rather than an absence of receptors in this muscle region. In this animal proximal receptors are scattered over the full extent of the orbital aponeurosis, including the most distal tips of tendon. The proximal global surface, with little tendon, contains only a few. As many as 23 and 12 receptors were counted in the SRM and LPS respectively. Their length varies from 250 to 1350 μm . The capsules are made of 2-7 layers of capsule cells, separated by thin lamellae of collagen with axial orientation. Like their counterparts in skeletal muscles, the capsule cells of the ocular receptors are continuous with the perineural cells of the supplying nerve.

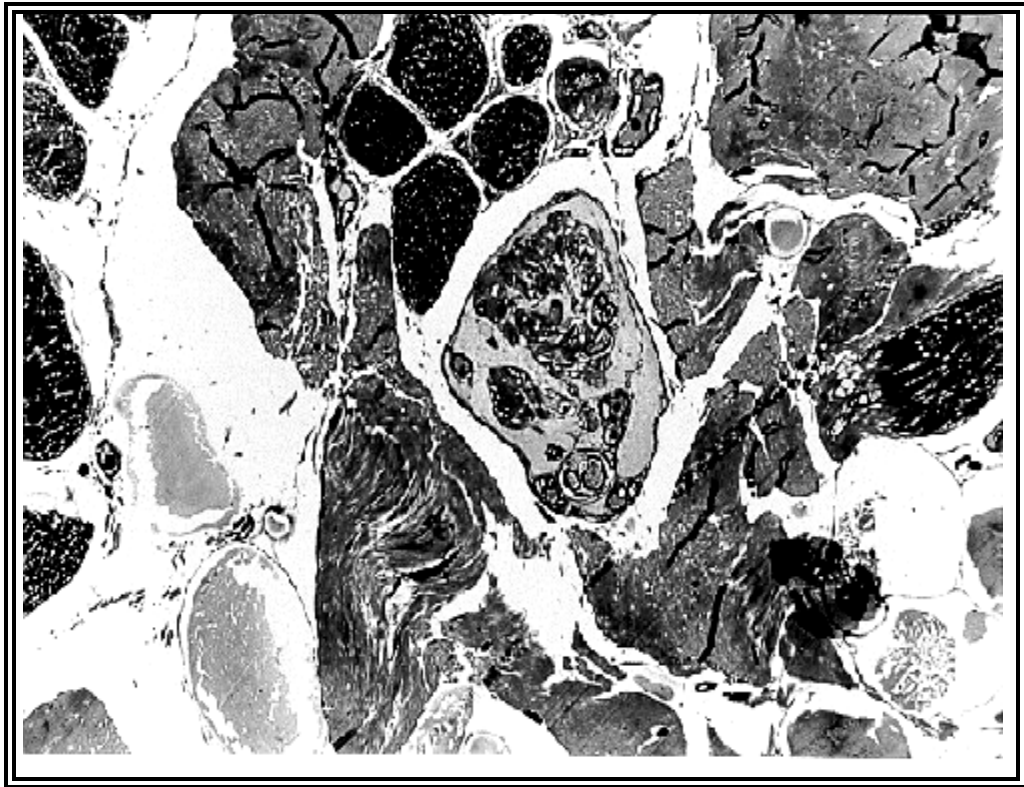


FIG. 3-12 MICROGRAPH OF A GTO IN SHEEP EOM, LM/TS, STAINED WITH TOLUIDINE BLUE

Although the structure of ocular GTOs in sheep complies rather well with conventional GTOs, certain modifications are observed. The collagen bundles

within the lumen of the receptors are grouped into columns, up to seven in number, and incompletely lined by fibroblast processes. In contrast to skeletal GTOs, these longitudinal compartments are separated by significantly larger fluid filled spaces, allowing very few columnar contacts within the central receptor body (Ruskell, 1979, 1990). The fluid spaces are gradually reduced to a minimum in the polar regions, leaving the distal and proximal ends with less than half of the central width. This arrangement gives the ocular tendon organs a far more fusiformed appearance than their counterparts in skeletal musculature. Although some receptors show regions surprisingly unoccupied by intracapsular structure, the bulk of collagen is rather constant along a GTO.

The supplying nerve, comprising 2-3 myelinated fibres, and a few blood vessels normally approaches the receptor from the muscle side. A few nerves, nonetheless, are seen to gain access from the opposite direction, through the body of the tendon. The nerves enter the GTO at any position along the length, mostly close to the polar regions. Their arborisation and distribution of unmyelinated nerve fibres within the collagen compartments follows the pattern of conventional GTOs. Many of the terminals are small and oval, thinly covered by Schwann cell processes and a basal lamina, whilst others form annular enclosures of the collagen bundles, usually completed by Schwann cell processes without a basal lamina. The density and spread of terminals varies from one receptor to the other, and some GTOs also possess compartments without neural ramifications.

In even greater contrast to GTOs of skeletal muscles, a minority of ocular GTOs in sheep have up to 3 muscle fibres entering the pole rather than just attaching externally to it. This unusual feature is also shared by the small and rare GTOs in monkey EOMs. Some of the fibres only advance a short distance while others continue deep into the receptor before terminating. Certain muscle fibres pass within the collagen columns, but the majority of them have a separate path, invested by thin, interrupted fibroblast processes. Regardless of their intracapsular course, all muscle fibres subsequently split into numerous finger-like processes and terminate in collagen bundles. These muscle fibres show morphological features

resembling Felderstruktur fibres. T-systems and sarcoplasmic reticulum are scarcely distributed in their sarcoplasm. The myofibrils have a close apposition, Z-lines are thick, the mitochondria small and infrequent, and motor terminals are occasionally present close to the fibre termination.

The presence of muscle fibres within the capsular lumen resembles the structural features of the immature GTO demonstrated in rat somatic musculature by Zelena and Soukup (1977). Based on this morphological similarity, some scientists argue that the ocular GTOs of sheep holding such peculiar features might have been retarded in their development (Ruskell, 1979).

Skeletal GTOs were initially classified as high threshold receptors in their response to passive stretch and later also as low threshold receptors in response to tension generated by normally contracting muscle fibres (Jami, 1992).

If GTOs, as firstly assumed, not only function as a muscle force regulator, but also respond differently to tension induced by the contracting muscle and passive stretch of the antagonist, this indicates that they may have a second role; contributor to eye movement sense (Ruskell 1999). Their presence would hence be of great significance, especially in the species lacking muscle spindles.

3.7 Palisade endings and myotendinous cylinders

Palisade endings (PEs) are a particular type of nerve endings, generally found in association with specific myotendinous complexes in the EOMs of several species. The name PEs was introduced by Dogiel (1906) and expresses the shape of the nerve endings. They are described as fine neural filaments appearing as a basket of terminals or a «palisade» around the extremity of one muscle fibre tip. PEs are presumed to be of sensory nature and probably occur exclusively in extrinsic eye muscles of mammals.

The term myotendinous cylinder (MTC) was introduced in a study by Ruskell in 1978. He investigated monkey EOMs and reported many MTCs in the distal myotendinous region. The nerve terminals showed large resemblance to PEs and, despite a few morphological differences, Ruskell categorized them to be of identical type. The nerve endings were enveloped by a capsule and since the other encapsulated receptors, muscle spindles and Golgi tendon organs, are named according to their shape and/or location, he suggested that the myotendinous end organ and the incorporated palisade endings should have a comparable description; “myotendinous” for location and “cylinder” for form.

In recent literature the terms palisade ending and myotendinous cylinder tend to be used interchangeably. In this literature review the receptor will be referred to as a MTC. The term palisade ending will only be applied when referring to the neural elements within the receptor.

Myotendinous cylinders were once incorrectly referred to as GTOs, due to a certain structural resemblance. More recent studies have revealed that ocular tendon receptors in fact hold several forms, some of them contrasting to such an extent from conventional GTOs that a subdivision of the ocular tendon receptors was found necessary. The unique structural features of MTCs are now well documented and the receptors are appreciated as separate proprioceptors (Barker, 1974; Ruskell, 1978; Alvarado-Mallart and Pinçon-Raymond, 1979; Billig et al., 1997; Ruskell, 1999; Kjellevold Haugen, 2001).

As described in the literature (Barker, 1974; Billig et al., 1997; Ruskell, 1999), numerous studies of extraocular tendon have revealed an extensive distribution of MTCs. Their occurrence is reported in cat (Dogiel, 1906; Tozer and Sherrington, 1910; Alvarado-Mallart and Pinçon-Raymond, 1979; Billig et al., 1997), rabbit (Tozer and Sherrington, 1910) and camel EOMs (Crevatin, 1902). MTCs are also found in monkey (Dogiel, 1906, Tozer and Sherrington; 1910; Ruskell, 1978), man (Dogiel, 1906, Richmond et al., 1984, Sodi et al., 1988, Lukas et al., 2000, Bruenech and Ruskell, 2000) and sheep (Blumer et al., 1998). Dogiel (1906) furthermore found them in dog, horse, and ox. Cooper and Daniel (1949), who re-described MTCs in humans, also noted briefly MTCs in proximal tendons. MTCs

were some years later also revealed in the proximal tendon of cat EOMs (Alvarado-Mallart and Pinçon-Raymond, 1979). No such receptors have been described in guinea pig (Aigner et al., 1997) or rat. Despite the wide distribution the proprioceptor is hence not be considered a general feature of mammalian EOMs. Whether they actually occupy both myotendinous poles in other species than man and cat, is yet also unknown.

About 50 MTCs have been counted in one single tendon of cat EOM (Alvarado-Mallart and Pinçon-Raymond, 1979). They were connected to some of the multiply innervated fibres of the global layer, distributed in both the distal and proximal muscle insertions of all EOMs (Alvarado-Mallart and Pinçon-Raymond, 1979). MTCs are even more numerous distributed in the distal tendon of monkey EOMs (Tozer and Sherrington, 1910; Ruskell, 1978). Nearly every Felderstruktur fibre of this species terminates in such an encapsulation and one rectus monkey muscle contained as many as 450, 19% of them lacking innervation. The receptors are found in the surrounding areas of myotendinous boundaries on both aspects of the extrinsic eye muscles in monkey, with a slightly greater incidence at the orbital surface. Whether or not they are present in the proximal region of monkey EOM has not been determined.

No exact numbers have been presented with respect to the distribution of MTCs in sheep EOMs. Blumer and co-workers (1998), who examined a medial rectus muscle from sheep, did however report that the receptors are numerous spread in distal myotendon, associated with Felderstruktur fibres of the global layer.

Myotendinous cylinders lie in series with the muscle fibres and are, like Golgi tendon organs, usually related to muscle fibres at one end of the receptor and tendon at the other. Their distribution in myotendinous junctions, encapsulation and innervation by axons terminating in intracapsular collagen as well as in the vicinity of muscle fibre tips have influenced several scientists to consider the nerve endings as sensory.

The receptors were proposed a sensory role by early authors such as Tozer and Sherrington (1910). However, results from their study on cat and monkey EOMs revealed that axons innervating these tendon structures ran within oculorotatory

nerves, leading other researchers to argue a motor function for the nerve terminal. When Cheng (1963) examined human EOMs histochemically and exposed cuffs of cholinesterase in the myotendinous junctions, he assumed he had stained the nerve endings and joined the supporters of a motor function. A degeneration of the MTCs following destruction of the oculorotatory cranial nerve nuclei (Sas and Schab, 1952) was by several scientists also thought to strengthen the hypothesis. Ruskell (1978), who was the first to undertake a detailed study of the ultra-structure of the receptor and its nerve supply, utterly supported the notion of an afferent nature. Alvarado-Mallart and Pinçon-Raymond (1979) came to the same conclusions in their study published shortly after. They based their arguments on the results revealed in their examination of monkey and cat EOMs respectively; the complex ultrastructure of these nerve endings as well as their intimate relation to both muscle fibre and bundles of tendon.

The current understanding is that nerves forming palisades within the MTCs are of a sensory nature. Histological studies of their ultrastructure and studies applying neuronal tracers convincingly report results that support an afferent origin (Ruskell, 1978; Alvarado-Mallart and Pinçon-Raymond, 1979, Billig et al., 1997). The cuffs of cholinesterase reported by Cheng (1963) are argued unrelated to MTCs, since all muscle fibres in EOMs and skeletal musculature show a high cholinesterase activity at their myotendinous junction (Couteaux, 1953) and MTCs are associated with only a small fraction of the muscle fibres. The fact that MTCs are associated with muscle fibres where motor innervation is already provided, equally favour a sensory function (Alvarado-Mallart and Pinçon-Raymond, 1979).

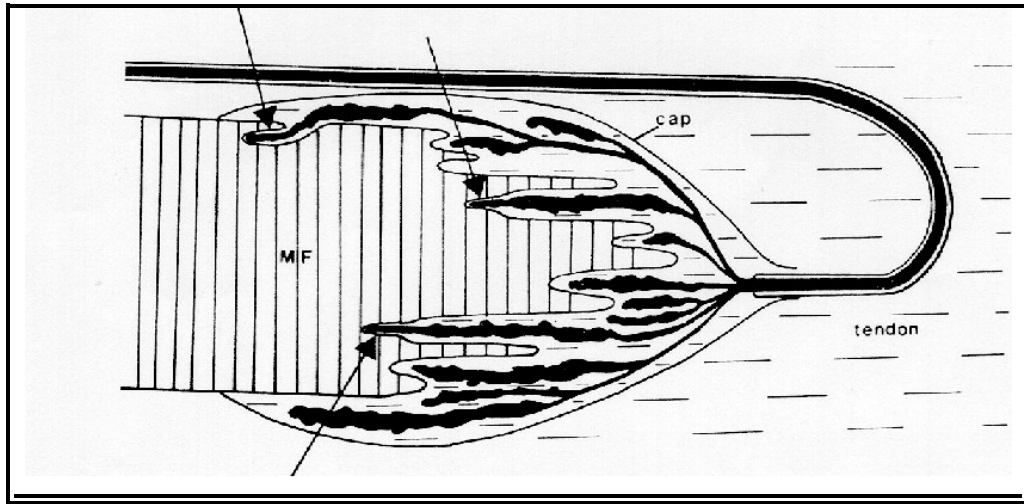


FIG. 3-13 PALISADE ENDINGS (ALVARADO-MALLART & PINÇON-RAYMOND, 1979). THE ARROWS ARE POINTING TOWARDS THE NEUROMUSCULAR CONTACTS. "MF" REPRESENTS MUSCLE FIBRE AND "CAP" CAPSULE.

The MTCs found in cat, monkey and sheep EOMs show only minor morphological differences (Alvarado-Mallart and Pinçon-Raymond, 1979; Ruskell, 1978, Blumer et al., 1998). They are encapsulated by 1-3, 4-9 and 3-5 lamellae of concentric over-lapping flat cells respectively. Unlike muscle spindles and GTOs, the capsule cells resemble fibrocytes. They are not continuous with the perineurium of the supplying nerve, nor do they generally form intracapsular septa.

A narrow extracellular space, sometimes penetrated by bundles of collagen and microfibrils, separates the cellular layers. The capsule is fairly cylindrical and in cat it constricts at the extremities to tightly enclose the collagen at one end and a muscle fibre at the other. In monkey the capsule forms a sleeve around the muscle fibres for then to continue forward into tendon, most commonly without constricting.

The capsular lumen is densely packed with collagen fibrils and fibrocytes in between. Processes of the latter produce an intracapsular network, but still leaves the bundles of collagen assembled in one compartment. There is little difference between the collagen within and outside the receptor.

There is generally one single muscle fibre associated with each receptor. The involved muscle fibres bear the same features as multiply innervated muscle fibres and are therefore categorized as Felderstruktur fibres. The diameter of the associated muscle fibres roughly gives the diameters of the receptors and the fibres, slightly increased in diameter at the level of the tips, are commonly found near the mid-point of the cylinders.

A few myotendinous cylinders in monkey EOMs have been seen accommodating more than one muscle fibre within the receptor and one muscle fibre has also been seen to split and contribute to two MTCs.

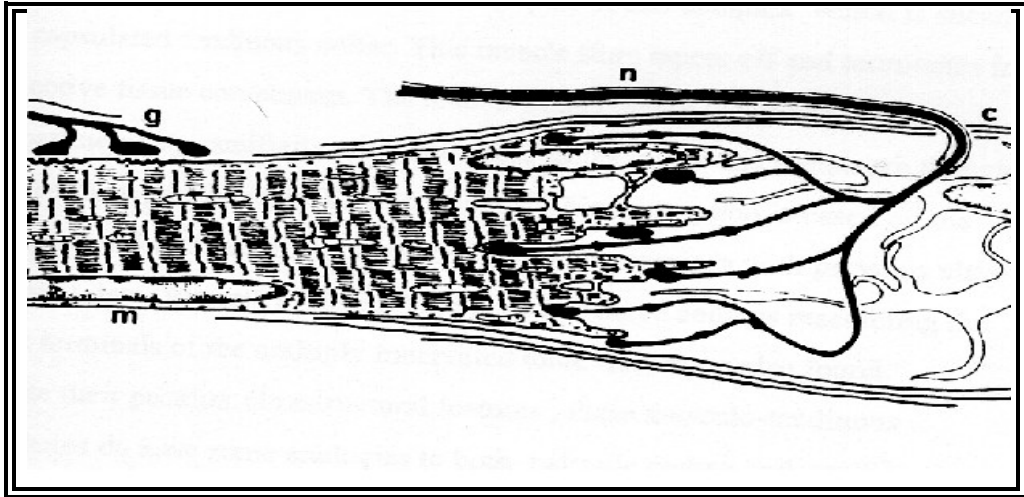


FIG. 3-14 MYOTENDINOUS CYLINDER (RUSKELL, 1978). "M" REPRESENTS THE MUSCLE, "G" ITS RELATED MOTOR NERVE, "N" THE SENSORY NERVE FIBRE OF THE PES AND "C" THE CAPSULE.

The innervating nerve advances through muscle in bundles of 2-4 (cat) and 1-7 (monkey) thinly myelinated axons. In monkey, an unmyelinated bundle occasionally also accompanies the myelinated fibres towards the MTC. The nerve fibres proceed into the tendon and then loop and return to the myotendinous region where they enter the collagenous end of the capsule to form palisade endings within the lumen. There is usually a one to one relation between receptor and number of supplying axons, but in some cat MTCs several axons are involved. Occasionally a single myelinated axon also splits to supply several neighbouring receptors in cat EOMs.

The axon penetrates the capsule at a tendon level or enters the capsule at the open tendinous end. It divides repeatedly as it enters the MTCs, loses its perineurium and myelin inside the capsule and subsequently ends as a multitude of varicose terminal ramifications in the myotendinous junction. The axon retains a Schwann cell's investment when it splits into preterminal branches inside the capsule. This is lost as the branches divide further and become terminal branches. The muscle fibre tip shows longitudinal infoldings of variable length and width in the myotendinous junction. Some nerve branches enter these longitudinal folds of the muscle fibre

and terminate on or in close vicinity to the muscle fibre tips. These axons attach externally to sarcolemmal sites free of myotendinous attachments. The majority of the axons in cat and sheep MTCs end amongst the bundles of collagen. In contrast, the majority of the nerve terminals in monkey MTCs attaches to the sarcolemma.

The myotendinous nerve terminals in human EOMs, initially found by Dogiel (1906), were later confirmed and described in detail in several studies (Cooper and Daniel, 1949; Richmond et al., 1984; Sodi et al., 1988; Bruenech and Ruskell, 2000). Dogiel (1906) referred to these structures as PEs, whilst Cooper and Daniel (1949), who seemed to have overlooked Dogiel's paper, regarded them as modified GTOs.

Their structure does, however, depart to such an extent from the receptors described in cat and monkey that they even have been implied incomparable with MTCs (Ruskell, 1999). They are very small (Sodi et al, 1988), but an essential difference is that many of them lack a distinct capsule, a feature generally associated with MTCs and a large range of other proprioceptors. The myotendinous complex is partly or completely surrounded by one thin layer of flat cells, sometimes just barely visible with electron microscopy (Sodi et al., 1988; Bruenech and Ruskell, 2000). The collagen and elastic fibres within the receptor is divided into compartments by ramified cells. The sensory nerve fibres, possessing different shapes and organelles, terminate very close to the muscle fibre tips. The associated muscle fibre is of Felderstruktur type (Bruenech and Ruskell, 2000). The distribution of these human receptors is also irregular, their frequency very low in some adults (Richmond et al., 1984) and even lower in infants, where none were found in the material investigated by Bruenech and Ruskell (1995). In addition to the age related difference in distribution, there is also a large inconsistency between individuals.

The enclosed, intimate organisation of palisade nerve endings, tendon and muscle fibre, may have special functional implications for the receptor's capacity to monitor eye movements. Like GTOs, MTCs probably propagate action potentials as a response to mechanical deformation of their intracapsular nerve endings. Their location and encapsulation, however, most likely protect the nerve terminals from

direct influence of external collagen movement and thus isolate the receptor from moderate passive stretch impacts (Ruskell, 1978; Richmond et al., 1984). Being associated with Felderstruktur fibres exclusively, it is also possible that proprioceptive signals are elicited by tension in the slow motor system only.

Some MTCs in rabbit, cat and monkey EOMs are supplied by nerves which give rise to collateral axons that originate near the recurrent loop and ultimately end like tendon organs in pure tendon (Tozer and Sherrington, 1910; Alvarado-Mallart and Pinçon-Raymond, 1979; Barker, 1974). Such a close arrangement, two different terminals formed by a single nerve fibre, may have an impact on their sensory function. Yet physiological evidence for duality in the sensory role of the receptors remains to be revealed, it has been suggested that the receptors may respond differently to passive stretch and active contraction, and hence be contributors to ocular position sense (Alvarado-Mallart and Pinçon-Raymond, 1979).

Like ocular GTOs of sheep, myotendinous cylinders to a certain degree resemble the immature tendon receptors demonstrated in somatic musculature of rat. An abundant number of clear vesicles are present in the terminal branches of MTCs (Ruskell, 1978; Alvarado-Mallart and Pinçon-Raymond, 1979; Richmond et al., 1984) and similar vesicles are numerous found in the developing sensory endings of skeletal GTOs as well (Zelena and Soukup, 1977). The unique neuromuscular contacts found in MTCs, but generally absent in other tendon receptors, are also a feature present in early stages of developing skeletal GTOs (Zelena and Soukup, 1977). The aggregation of vesicles in MTCs is however unlike the relatively scattered vesicle content normally found in sensory terminals (Harker, 1972; Barker, 1974). The nature of these vesicles is undefined, but a neurotrophic role has been implied in the developing GTO. Based on the morphology of the receptors, Baker (1974) has suggested that MTCs are a particular type of tendon organ in which the neuromuscular contacts established during development have been retained and elaborated.

4. Postscript

This study has been undertaken to present an overview of the afferent components of the mammalian oculomotor systems, with emphasis on sensory receptors present in the extraocular muscles, and secondarily to present the current theories of the potential role of proprioception in oculomotor control.

The morphological features of the various receptors are essential in the understanding of oculomotor control and have consequently been comprehensively covered in this document. Micrographs presented in the current study, illustrating some of these histological elements, were taken under light microscopic examination of extraocular muscles. The tissues were obtained from selected species within the animal kingdom and prepared for microscopy according to standard histological procedures.

Most of the information presented in the current manuscript was obtained through previous research undertaken by the author (Kjellefold Haugen, 2001). Recently published information regarding sensory receptors and their potential role in development and maintenance of binocular vision has been added to provide the reader with an updated literature review. The current document and the preceding publication regarding extraocular muscle morphology and their efferent innervation, will hopefully find applications as reference manuals in academic institutes teaching visual science.

5. List of illustrations

FIG. 3-1 THE AFFERENT AND EFFERENT COMPONENTS OF THE CENTRAL AND PERIPHERAL NERVOUS SYSTEM	7
FIG. 3-2 ILLUSTRATION OF HOW RECEPTORS DETECT STIMULI: A) BY THE PERIPHERAL END OF A SENSORY NEURON, B) BY THE PERIPHERAL NERVE ENDING INTERMINGLING AMONG CELLS AND/OR EXTRACELLULAR ELEMENTS, C) BY SPECIAL, OFTEN NON-NEURAL, CELLS DETECTING STIMULI AND THEN ACTIVATING THE PERIPHERAL SENSORY NERVE ENDING. D RESEMBLES C, BUT IS ENTIRELY LOCATED WITHIN THE CNS.....	7
FIG. 1-3 ILLUSTRATION OF THE HYPOTHESIS WHERE VISION, Efference COPY AS WELL AS PROPRIOCEPTION ARE THOUGHT TO CONTRIBUTE TO OCULOMOTOR CONTROL	11
FIG. 1-4 ILLUSTRATION OF THE EYE PRESSURE METHOD APPLIED BY STARK AND BRIDGEMAN (1983)	13
FIG. 3-6 HUMAN SPIRAL NERVE ENDING (RUSKELL, 1999). "N" REPRESENTS MOTOR NERVE, "M" MUSCLE FIBRE, "S" SHEATH AND "E" NERVE ENDING.....	23
FIG. 3-7 MICROGRAPH OF A MUSCLE SPINDLE IN SHEEP EOM, LM/TS, STAINED WITH TOLUIDINE BLUE	25
FIG. 3-8 SCHEMATIC DIAGRAM OF THE LOCATION AND INNERVATION OF MUSCLE SPINDLE AND GOLGI TENDON ORGAN IN CAT SKELETAL MUSCLE (BARKER, 1974).....	27
FIG. 3-9 GOLGI TENDON ORGAN (SCHOULTZ AND SWETT, 1972). "A" REPRESENTING THE MUSCLE FIBRE TO WHICH THE GTO IS ATTACHED, "B" THE MUSCULAR POLE, "C" THE ENTRY OF THE SENSORY NERVE, "D" THE WIDEST PART OF THE CAPSULE, "E" THE TENDINOUS POLE AND "T" THE TENDON.....	29
FIG. 3-10 DEVELOPMENT OF GTOs IN RAT SKELETAL MUSCLE (ZELENA AND SOUKUP, 1977). "A" REPRESENTS DAY 21 GESTATION, "B" 3 DAYS AFTER BIRTH, "C" 5 DAYS AFTER BIRTH AND "D" 14 DAYS AFTER BIRTH.....	33
FIG. 3-11 THE CLOSE RELATIONSHIP BETWEEN COLLAGEN AND NERVE ENDINGS WITHIN A GTO (SCHOULTZ AND SWETT, 1972). THE ARROW POINTING TOWARDS THE NEURAL TISSUE.....	33
FIG. 3-12 MICROGRAPH OF A GTO IN SHEEP EOM, LM/TS, STAINED WITH TOLUIDINE BLUE	35
FIG. 3-13 PALISADE ENDINGS (ALVARADO-MALLART & PINCON-RAYMOND, 1979). THE ARROWS ARE POINTING TOWARDS THE NEUROMUSCULAR CONTACTS. "MF" REPRESENTS MUSCLE FIBRE AND "CAP" CAPSULE.....	41
FIG. 3-14 MYOTENDINOUS CYLINDER (RUSKELL, 1978). "M" REPRESENTS THE MUSCLE, "G" ITS RELATED MOTOR NERVE, "N" THE SENSORY NERVE FIBRE OF THE PES AND "C" THE CAPSULE.....	42

6.List of symbols and abbreviations used in text

#	Number of
µm	Micron
ACh	Acetylcholine
AChE	Acetylcholinesterase
CNS	Central nervous system
EM	Electron microscopy
EOM	Extraocular muscle
GL	Global layer
GTO	Golgi tendon organ
IOM	Inferior oblique muscle
IRM	Inferior rectus muscle
LM	Light microscopy
LPS	Levator palpebrae superioris
LRM	Lateral rectus muscle
MRM	Medial rectus muscle
MS	Muscle spindle
MTC	Myotendinous cylinder
nm	Nanometer
OL	Orbital layer
PE	Palisade ending
PNS	Peripheral nervous system
SOM	Superior oblique muscle
SR	Sarcoplasmic reticulum
SRM	Superior rectus muscle
T-system	Transverse tubule system
TS	Transverse section

7. Bibliography

Aigner, M., Lukas, J.R., Denk, M. and Mayr, R. (1997) Sensory Innervation of the Guinea Pig Extraocular Muscles: A 1,1-Dioctadecyl-3,3,3'-Tetramethylindocarbocyanine Perchlorate Tracing and Calcitonin Gene-Related Peptide Immunohistochemical Study. *J. Comp. Neur.* **380**, 16-22

Aigner, M., Lukas, J.R., Denk, M., Ziya-Ghazvini, F., Kaider, A. and Mayr, R. (2000) Somatotopic Organization of Primary Afferent Perikarya of the Guinea-pig Extraocular Muscles in the Trigeminal Ganglion: a Post-mortem Dil-tracing Study. *Exp. Eye Res. Apr.* **70 (4)**, 411-418

Aigner, M., Lukas, J.R. and Mayr, R. (1989) Zur Frage der Propriozeption in ausseren Augenmuskeln (EOM): Untersuchungen am Meerschweinchen. *85. Versammlung der Anatomischen Gesellschaft*, 7

Albert, D.M. and Edwards, D.D. (1996) The History Of Ophthalmology, Blackwell Science, Oxford

Alvarado, J.A. and Van Horn, C. (1975) Muscle cell types of the cat inferior oblique. In Basic Mechanisms of Ocular Motility and Their Clinical Implications (Lennerstrand and Bach-y-Rita eds.), pp 15-45, Pergamon Press, Oxford

Alvarado-Mallart, R.-M. and Pinçon-Raymon, M. (1979) The palisade endings of cat extraocular muscles: a light and electron microscope study. *Tissue Cell* **11**, 567-584

Ashton, J.A., Dean, S.R., Milleret, C., Donaldson, I.M.L. (1988) Afferent signals from cat extraocular muscles in the medial vestibular nucleus, the nucleus prepositus hypoglossi and adjacent brainstem structures. *Neuroscience* **26**, 131-146

Bach-y-Rita, P. and Ito, F. (1966) Properties of stretch receptors in cat extraocular muscles. *J. Physiol.* **186**, 663-688

Bach-y-Rita, P. and Lennerstrand, G. (1975) Absence of polyneuronal innervation in cat extraocular muscles. *J. Physiol. (Lond.)* **244**, 613-624

Baker, R., Precht, W. and Llinas, R. (1972) Mossy fibre climbing projections of extraocular afferents to cerebellum. *Brain Res.* **38**, 440-445

Barker, D. (1962) The structure and distribution of muscle receptors. In Symposium on Muscle Receptors (Barker ed.), pp 227-240, Hong Kong University press, Hong Kong.

- Barker, D. (1974) The morphology of muscle receptors. In Muscle Receptors. Handbook of sensory physiology, Vol III/2 (Hunt ed.), pp 1-190, Springer Verlag, Berlin
- Batini, C., Buisseret-Delmas, C. and Kado, R.T. (1979) On the fibres of the III,IV and VI cranial nerves of the cat. *Arch. Ital. Biol.* **117**, 111-122
- Berry M.M., Stranding S.M. and Bannister L.H.(1995) Nervous system. In Grays anatomy. pp 901-1363
- Billig, I., Buisseret-Delmas, C. and Buisseret, P. (1997) Identification of nerve endings in cat extraocular muscles. *Anat. Rec.* **248**, 566-575
- Blumer, R., Lukas, J.R., Wasicky, R. and Mayr, R. (1998) Presence and structure of innervated myotendinous cylinders in sheep extraocular muscles. *Neurosci. Lett.* **248**, 49-52
- Blumer, R., Lukas, J.R., Aigner, M., Bittner, R., Baumgartner, I. and Mayr, R. (1999) Fine structural analysis of extraocular muscle spindles of a two-year-old infant. *Inv. Ophthalm. Vis. Sci.* **40**, 55-64
- Blumer, R., Lukas, J.R., Wasicky, R. and Mayr, R. (2000) Presence and morphological variability of Golgi tendon organs in the distal portion of sheep extraocular muscle. *Anat Rec.* **258(4)**, 359-68.
- Bonavolonta, A. (1956) Ricerche comparative sulle espansioni nervose sensitive nei muscolo estrinseci dell'occhio dell'uomo e di altri mammiferi. 2. Gli organi musculo-tendinei di Golgi. *Quad. Anat. Prat.* **11**, 151-166
- Bridgeman, B. and Graziano, J.A. (1989) Effect of context and efference copy on visual straight ahead. *Vis. Res.* **29**, 1729-1736
- Bridgeman, B. and Stark, L. (1991) Ocular proprioception and efference copy in registering visual direction. *Vis. Res.* **31**, 1903-1913
- Bridgeman, C.F. (1968) The structure of tendon organs in the cat: a proposed mechanism for responding to muscle tension. *Anat. Rec.* **162**, 209-220
- Bridgeman, C.F. (1970) Comparison in structure of tendon organs in the rat, cat and man. *J. Comp. Neur.* **138**, 369-372
- Brindley, G.S., Goodwin, G.M., Kulikowski, J.J. and Leighton, D. (1976) Proceedings: Stability of vision with a paralysed eye. *J Physiol.* **258(2)**, 65-66.
- Brindley, G.S. and Merton, P.A. (1960) The absence of position sense in the human eye. *J. Physiol.* **153**, 127-130

- Brodal, P. (1990) The sensory system. In Structure and function of the central nervous system. pp 109-176 TANO A.S., Oslo
- Browne, J.S. (1975) The responses of muscle spindles in sheep extraocular muscles.
J. Physiol. **251**, 483-496
- Bruenech, J.R. and Ruskell, G.L. (1993) Extraocular muscle spindles in infants.
Ophthalm. Physiol. Opt. **13**, 104
- Bruenech, J.R. and Ruskell, G.L. (1995) Tendon receptors in human extraocular muscles. *Vis. Res.* **35**, S322
- Bruenech, J.R. and Ruskell, G.L. (2000) Myotendinous Nerve Endings in Human Infant and Adult Extraocular Muscles. *Anat. Rec.* **260**, 132-140
- Bruenech, J.R. and Ruskell, G.L. (2001) Muscle spindles in the extraocular muscles of human infants. *Cells, Tissues and Organs*
- Brzezinski, D.K. (1961) Untersuchungen zur Histochemie der Muskelspindeln. II Mitteilung: Zur Topochemie und Funktion des Spindelraumes und der Spindelkapsel. *Acta Histochem.* **12**, 277-288
- Buisseret, P. and Maffei, L. (1977) Extraocular proprioceptive projections to the visual cortex. *Exp. Brain Res.* **28**, 421-426
- Buisseret-Delmas, C. (1976) Parcours trigeminal des fibres sensorielles provenant des muscles extrinseques de l'oeil chez le chat. *Arch. Ital. Biol.* **114**, 341-356
- Burke, R.E., Levine, D.N., Tsairis, P. and Zajac, F.E. (1973) Physiological types and histochemical profiles in motor units of the cat gastronemius.
J. Physiol. **234**, 723-748
- Burkitt, H.G., Young, B. and Heath, J.W. Functional Histology, 3. ed, Churchill Livingstone
- Buzzard, E.F. (1908) A note on the occurrence of muscle spindles in ocular muscles. *Proc. R. Soc. Med.* **1**, 83-88
- Campos, E.C., Chiesi, C. and Bolzani, R. (1986) Abnormal spatial localization in patients with herpes zoster ophthalmicus. *Arch. Ophthalm.* **104**, 1176-1177
- Carpenter, R.H.S. (1977) Movements of the eyes. Pion Limited, London
- Carpenter, R.H.S. (1988) Movements of the eyes, 2nd. Ed, Pion Limited, London
- Cheng, K. (1963) Cholinesterase activity in human extraocular muscles.
Jap. J. Ophthalm. **7**, 174-183

Cheng, K. and Breinin, G.M. (1965) Fine structure of nerve endings in extraocular muscle. *Arch. Ophthalmol.* **74**, 822-834

Cheng, K. and Breinin, G.M. (1966) A comparison of the fine structure of extraocular and interosseus muscles in the monkey. *Invest. Ophthalmol.* **5**, 535-549

Cheng-Minoda, K., Davidowitz, J., Liebowitz, A.D., Breinin, G.M. (1968) Fine structure of extraocular muscle in rabbit. *J. Cell Biology* **39**, 193-549

Chiarandini, D.J. and Davidowitz, J. (1979) Structure and function of extraocular muscle fibres. In Current topics in Eye Research, Vol. 1, (Zadunaisky and Davison eds.), pp. 91-142, Academic Press, New York

Cilimbaris, P.A. (1910) Histologische Untersuchungen über die Muskelspindeln der Augenmuskeln. *Arch. Mikr. Anat.* **75**, 692-747

Cooper, S. and Daniel, P.M. (1949) Muscle spindles in human extrinsic eye muscles. *Brain* **72**, 1-24

Cooper, S., Daniel, P.M. and Whitteridge, D. (1955) Muscle spindles and other sensory endings in the extrinsic eye muscles: the physiology and anatomy of these receptors and of their connections with the brain-stem. *Brain* **78**, 564-583

Cooper, S. and Fillenz, M. (1955) Afferent discharges in response to stretch from the extraocular muscles of the cat and monkey and the innervation of these muscles. *J. Physiol.* **127**, 400-413

Couteaux, R. (1953) Particularites histochemiques des zones d'insertion du muscle strie. *Cr. Seanc. Soc. Biol. (Paris)* **147**, 1974-1976

Couteaux, R. (1955) Morphological and cytochemical observations on the post-synaptic membrane of motor end-plates and ganglion synapses. *Exp. Cell Res. (Suppl.)* **5**, 294-322

Crevatin, F. (1902) Su Di alcune forma di terminazioni nervose nei muscoli dell'occhio del dromedario. *Rend. Sess. Roy. Accad. Sci. Ist. Bologna* **6**, 57-61

Daniel, P.M. (1946) Spiral nerve endings in the extrinsic eye muscles. *J. Anat.* **80**, 189-193

Davidowitz, J., Pachter, B.R., Philips, G. and Breinin, G.M. (1976) Structural alterations of the junctional region in extraocular muscle of dystrophic mice. I. Modifications of sole-plate nuclei. *Am. J. Pathol.* **82 (01)**, 101-110.

Davidowitz, J., Philips, G. and Breinin, G.M. (1977) Organization of the orbital surface layer in rabbit superior rectus. *Invest. Ophthalmol. Vis. Sci.* **16**, 711-729

Dengis, C.A., Steinbach, M.J. and Kraft, S.P. (1998) Registered eye position: short and long term effects of botulinum toxin injected into the eye muscle. *Exp. Brain Res.* **119**, 475-482

Dietert, S.E. (1965) The demonstration of different types of muscle fibres in human extraocular muscles by electron microscopy and cholinesterase staining. *Invest. Ophthalmol.* **4**, 51-63

Dogiel, A.S. (1906) Die Endigungen der sensiblen Nerven in den Augenmuskeln und deren Sehnen beim Menschen und den Säugetieren. *Arch. Mikr. Anat.* **68**, 501-506

Donaldson, I.M.L. and Long, A.C. (1980) Interaction between extraocular proprioceptive and visual signals in the superior colliculus of the cat. *J. Physiol.* **298**, 85-110

Durston, J.H.J. (1974) Histochemistry of primate extraocular muscles and the changes of denervation. *Br. J. Ophthalmol.* **58**, 196-216

Eggers, H.M. (1982) Functional anatomy of the extraocular muscles. In Ocular Anatomy, Embryology and Teratology (Jakobiec ed.), pp 783-824, Harper & Row

Fernand, V.S.V. and Hess, A. (1969) The occurrence, structure and innervation of slow and twitch muscle fibres in the tensor tympani and stapedius of the cat. *J. Physiol. (Lond.)* **200**, 547-554

Fiorentini, A. and Maffei, L. (1977) Instability of the eye in the dark and proprioception. *Nature (Lond.)* **269**, 330-331

Gairns, F.W. (1930) A modified gold chloride method for the demonstration of nerve endings. *Q.J. Microsc. Sci.* **74**, 151-153

Gary-Bobo, E., Milleret, C. and Buisseret, P. (1986) Role of eye movements in developmental processes of orientation selectively in the kitten visual cortex. *Vis. Res.* **26**, 557-567

Gauthier, G.M., Mommay, D. and Vercher, J.-L. (1990) Ocular muscle proprioception and visual localization of targets in man. *Brain* **113**, 1857-1871

Gauthier, G.M., Vercher, J.-L. and Blouin, J. (1995) Egocentric visual target position and velocity coding: role of ocular muscle proprioception. *Ann. Biomed. Engin* **23**, 423-435

Gomez-Barrena, E., Martinez-Moreno, E., Ballesteros Masso, R., Martinez, D. and Munuera Martinez, L. (1999) Gold chloride technique to study articular innervation. A protocol validated through computer-assisted colorimetry. *Histol. Histopathol.* **14**, 69-79

- Graves, A., Trotter, Y. and Fregnac, Y. (1987) Role of extraocular muscle proprioception in the development of depth perception in cats. *J. Neurophysiol.* **85**, 816-831
- Greene, T. and Jampel, R. (1966) Muscle spindles in the extraocular muscles of macaque. *J. Comp. Neur.* **126**, 547-550
- Guthrie, B.L., Porter, J.D. and Sparks, D.L. (1983) Corollary discharge provides accurate eye position information to the oculomotor system. *Science, N.Y.* **221**, 1193-1195
- Hain, A. and Diamond, R. (1983) Contribution of eye movement to the representation in space. In Spatially orientated behaviour (Hain and Jeannerod eds.), pp 119-133, Springer
- Ham, A.W. and Cormack, D.H., (1978) In Histology 8 ed. (Ham and Cormack eds.), Lippincott
- Han, Y. and Lennerstrand, G. (1995) Eye movements in normal subjects induced by vibratory activation of neck muscle proprioceptors. *Acta Ophthalmol. Scand.* **73**, 414-416
- Harker, D.W. (1972) The structure and innervation of sheep superior rectus and levator palpebrae extraocular muscles. *Invest. Ophthalmol.* **11**, 970-979
- Hess, A. (1960) Structural differences of fast and slow extrafusal muscle fibres and their nerve endings in chickens. *J. Physiol. (Lond.)* **157**, 221
- Hess, A. (1961) The structure of slow and fast extraocular muscle fibres and their nerve endings in guinea pigs. *J. Cell Comp. Physiol.* **58**, 63-80
- Hess, A. (1967) The structure of vertebrate slow and twitch muscle fibres. *Invest. Ophthalmol.* **6**, 217-228
- Hess, A. and Pilar, G. (1963) Slow fibres in the extraocular muscles of cat. *J. Physiol. (Lond.)* **169**, 780-798
- Hines, M. (1931) Studies on the innervation of skeletal muscle. III Innervation of the extrinsic eye muscles of the rabbit. *Am. J. Anat.* **47**, 1-53
- Houk, J. and Hennemann, E. (1967) Responses of Golgi tendon organs to active contractions of the soleus muscle of the cat. *J. Neurophysiol.* **30**, 466-481
- Howard, I.P. (1982) Human Visual Orientation, Wiley and Sons, Toronto.
- Huber, G.C. (1900) Sensory nerve terminations in the tendons of the extrinsic eye-muscles of the cat. *J. Comp. Neur.* **10**, 152-158

- Hunt, C.C. (1974) The physiology of muscle receptors. In Muscle Receptors. Handbook of Sensory Physiology, Vol. III/2 (Hunt ed.), pp. 191-234. Springer Verlag, Berlin
- Irvine, S.R. and Ludvigh, E.J. (1937) Is ocular proprioceptive sense concerned in vision? *Arch. Ophthalmol.* **15**, 1037-1049
- Ishida, N., del Cerro, M., Rao, G.N., Mathe, M. and Aquavella, J.V. (1984) Corneal stromal innervation. A quantitative analysis of distribution. *Ophthalmol. Res.* **16**, 139-144
- Jacobiéc, F.A. (1982) Ocular adnexa. In Ocular Anatomy, Embryology and Teratology (Jakobiéc ed.), pp 783-824, Harper & Row
- Jacot, J.L., Glover, J.P. and Robinson jr., G. (1995) Improved Gold Chloride Procedure for Nerve Staining in Whole Mounts of Rat Corneas. Biotechnic & histochemistry. Baltimore. Williams & Wilkins.
- Jami, L. (1992) Golgi tendon organs in mammalian skeletal muscle: functional properties and central actions. *Physiol. Rev.* **72**, 623-666
- Juinquiera, L.C., Carneiro, J. and Kelley, R.O. (1989) Basic Histology 6 edition, Lange Medical books
- Kato, T. (1938) Uber histologische Untersuchungen der Augenmuskeln von Menschen und Säugetieren. *Okajimas Folia Anat. Jap.* **16**, 131-145
- Keller, E.L. and Robinson, D.A. (1971) Absence of a stretch reflex in extraocular muscles of the monkey. *J. Neurophysiol.* **34**, 908-919
- Kern, R. (1965) A comparative pharmacologic-histologic study of slow and twitch fibres in the superior rectus muscle of the rabbit. *Invest. Ophthalmol.* **4**, 901-910
- Kerns, J.M. (1980) Postnatal differentiation of the rat trochlear nerve. *J. Comp. Neur.* **189**, 291-306
- Kjellevold Haugen, I.-B. (2001) Comparison of proximal tendon receptors in extraocular muscles. Thesis
- Krüger, P. (1949) Die innervation der tetanischen und tonischen Fasern der quergestreiften Skelettmuskulatur der Wirbeltiere. *Anat. Anz.* **97**, 169-175
- Kupfer, C. (1960) Motor innervation of extraocular muscle. *Ibid.* **153**, 522-526
- Leksell, L. (1945) The action potential and excitatory effects of the small ventral root fibres to skeletal muscle. *Acta Physiol. Scand.* **10**, 1-84

- Lennerstrand, G. (1981) Functional Basis of Ocular Motility Disorders (Lennerstrand and Zee & Keller eds.), Pergamon Press, New York
- Lewis, R.F., Zee, D.S., Gaymard, B.M. and Guthrie, B.L. (1994) Extraocular muscle proprioception functions in the control of ocular alignment and eye movement conjugacy. *J. Neurophysiol.* **72**, 1028-1031
- Locket, N.A. (1968) The dual nature of human extraocular muscle. *Br. Orthoptic Journal* **25**, 2-11
- Ludvigh, E. (1952) Possible role of proprioception in the extraocular muscles. *Arch. Ophthalmol.* **48**, 436-440
- Ludvigh, E. (1952) Control of ocular movements and visual interpretation of environment. *Arch. Ophthalmol.* **48**, 442-448
- Lukas, J. R., Aigner, M., Blumer, R., Heinzl, H. and Mayr, R. (1994) Number and distribution of neuromuscular spindles in human extraocular muscles. *Invest. Ophthalmol. Vis. Sci.* **35**, 4317-4327
- Lukas, J.R., Blumer, R., Aigner, M., Denk, M., Baumgartner, I. and Mayr, R. (1997) Proprioception aus ausseren Augenmuskeln des Menschen: zur mophologie ihrer Muskelspindeln. *Klin. Monats. Augenheilk.* **211**, 183-187
- Lukas, J.R., Blumer, R., Denk, M., Baumgartner, I., Neuhuber, W. and Mayr R. (2000) Innervated Myotendinous Cylinders in Human Extraocular Muscles. *Invest. Ophthalmol. & Visual Science* **41**, 2422-2431
- Maier, A., DeSantis, M. and Eldred, E. (1975) The occurrence of muscle spindles in extraocular muscles of various vertebrates. *J. Morph.* **143**, 397-408
- Manni, E. and Bortolami, R. (1979) Peripheral and central organization of the extraocular muscle proprioception in the unculata. In Reflex control of Posture and Movement, Progress in Brain Research Vol. 50 (Granit and Pompeiano eds.), pp. 291-299 Elsevier, Amsterdam.
- Manni, E. and Bortolami, R. (1981) Proprioception in eye muscles. In Functional Basis of Ocular Motility Disorders (Lennerstrand and Zee & Keller eds.), pp 55-67, Pergamon Press, New York
- Marchi, V. (1882) Ueber die Terminalorgane der Nerven (Golgi's Nervenkorperchen) in den sehnen der Augenmuskeln. *Graefes Arch. Ophthalmol.* **28**, 203-212
- Matin, L. (1976) A possible hybrid mechanism for modification of visual direction associated with eye movements - the paralyzed eye experiment reconsidered. *Perception* **5**, 223-239

- Matin, L. (1986) Visual localization and eye movements. In Handbook of Perception and Human Performance, Vol.I, Sensory Processes and Perception (Boff, Kaufman and Thomas eds.), pp. 1-46. Wiley, New York.
- Matin, L., Picoult, E., Stevens, J.K., Edwards Jr, M.W., Young, D. and MacArthur, R. (1982) Oculoparalytic illusion: Visual-field dependent spatial mislocalizations by humans partially paralyzed with curare. *Science* **316**, 198-201
- Mayr, R. (1971) Structure and distribution of fibre types in the external eye muscles of the rat. *Tissue Cell* **3**, 433-462
- Mayr, R. (1975) Discussion remarks. In Basic mechanisms of ocular motility and their clinical implications. (Lennerstrand and Bach-y-Rita eds.) pp 43-45, Pergamon Press, New York
- Mayr, R. (1978) Functionelle Morphologie der Augenmuskeln. In Disorders of Ocular Motility-Neurophysiological and Clinical Aspects. (Kommerell ed.), pp. 1-15, Bergmann Verlag, Munchen,
- Mayr, R., Stockinger, L. and Zenker, W. (1966) Elektronenmikroskopische untersuchungen an unterschiedlich innervierten muskelfasern der ausseren augenmuskulatur des rhesesaffen. *Z. Zellforsch. Mikrosk. Anat.* **75**, 434-452
- McCouch, G.P. and Adler, F.H. (1932) Extraocular reflexes. *Am. J. Physiol.* **100**, 78-88
- Meredith, M.A. and Goldberg, S.J. (1986) Contractile differences between muscle units in the medial rectus muscle and lateral rectus muscle in cat. *J. Neurophysiol.* **56**, 50-62
- Merrillees, N.C.R., (1962) Some observations on the fine structure of a golgi tendon organ i the rat. In Symposium on Muscle Receptors (Barker ed.), pp. 199-206, Hong Kong University Press
- Merrillees, N.C.R., Sunderland, S. and Hayhow, W. (1950) Neuromuscular spindles in the extraocular muscles of man. *Anat. Rec.* **108**, 23-30
- Miller, J.E. (1967) Cellular organization of rhesus extraocular muscle. *Invest. Ophthalmol.* **6**, 18-39
- Miller, J.E (1975) Ageing changes in extraocular muscles. In Basic mechanisms of ocular motility and their clinical implications (Lennerstrand and Bach-y-Rita eds.), Pergamon Press, New York
- Morgan, D.L. and Proske, U. (1984) Vertebrate slow muscle: its structure, pattern of innervation, and mechanical properties. *Physiol. Rev.* **64**, 103-169.
- Namba, T., Nakamura, T., Takahashi, A. and Grob, D. (1968) Motor nerve endings in extraocular muscles. *J. Morphol.* **30**, 433-453

- Optican, L.M., Zee, D.S. and Chu, F.C. (1985) Adaptive response to ocular weakness in human pursuit and saccadic eye movements. *J. Neurophysiol.* **54**, 110-122
- Pachter, B.R., Davidowitz, J. and Breinin, G.M. (1976) Light and electron microscopic serial analysis of mouse extraocular muscle: morphology, innervation and topographical organization of component fibre populations. *Tissue Cell* **8**, 547-560
- Page, S.G. (1965) A comparison of the fine structure of frog slow and twitch muscle fibers. *J. Cell Biology* **26**, 477-497
- Palmieri, G., Panu, R., Asole, A., Farvina, V. and Sanna, L. (1985) Sensory nerve endings in the peroneus tertius muscle of the ass and horse: a functional hypothesis. *Arch. Anat. Histol. Embryol.* **68**, 37-47
- Peachey, L. (1971) The structure of the extraocular muscle fibers of mammals. In The Control of Eye Movements (Bach-y-Rita, Collins and Hyde eds.), pp 47-66, Academic Press, New York
- Peachey, L.D., Hudson, C. and Bach-y-Rita, P. (1972) Marking extraocular muscle fibres for physiological-morphological correlation. *Proc. XXV Int. Congr. Physiol. Sci. (Munich)*, 443.
- Peachey, L.D. and Huxley, A.F. (1962) Structural identification of twitch and slow striated muscle fibres of the frog. *J. Cell Biology* **13**, 177-180
- Peachey, L.D., Takeichi, M. and Nag, A.C. (1974) Muscle fibre types and innervation in adult cat extraocular muscles. In Exploratory Concepts in muscular Dystrophy, Amsterdam Experta Medica Foundation vol II, pp 246-254
- Pilar, G. (1967) Further study of the electrical and mechanical responses of slow fibres in cat extraocular muscles. *J. Gen. Physiol.* **50**, 2289-2300
- Pilar, G. and Hess, A. (1966) Differences in internal structure and nerve terminals of the slow and twitch muscle fibers in the cat superior oblique. *Anat. Rec.* **154**, 243-252
- Polyak, S. (1957) The Vertebrate Visual system. (Klüver ed.), The university of Chicago Press, Chicago and London
- Porter, J.D. (1986) Brainstem terminations of extraocular muscle primary afferent neurons in the monkey. *J. Comp. Neur.* **247**, 133-143
- Porter, K.R. and Palade, G.E. (1957) Studies of the endoplasmic reticulum. III. Its form and distribution in striated muscle cells. *J. Biophys. Biochem. Cytol.* **3**, 269-300

- Prince, J., Diesem, C.D., Eglitis, I. and Ruskell, G.L (1960) Anatomy and Histology of the eye and orbit in domestic animals, C.C. Thomas, USA
- Reynolds, E.S. (1963) The use of lead citrate at high pH as an electron-opaque stain in electron microscopy. *J. Cell. Biology* **17**, 208-212
- Rheuben, M.B. and Schaner, P.J. (1989) The use of gold chloride to stain developing and adult neuromuscular junctions in the insect. *Stain Technol.* **64**, 155-162
- Richmond, B.R. and Wurtz, R.H. (1980) Vision during saccadic eye movements. II. A corollary discharge to monkey superior colliculus. *J. Neurophysiol.* **43**, 1156-1167
- Richmond, F.J.R., Johnston, W.S.W., Baker, R.S. and Steinbach, M.J. (1984) Palisade endings in human extraocular muscles. *Invest. Ophthalmol. Vis. Sci.* **25**, 471-476
- Ruskell, G.L. (1978) The fine structure of innervated myotendinous cylinders in extraocular muscles of Rhesus monkeys. *J. Neurocytol.* **7**, 693-708
- Ruskell, G.L. (1979) The incidence and variety of Golgi tendon organs in extraocular muscles of the rhesus monkey. *J. Neurocytol.* **8**, 639-653
- Ruskell, G.L. (1983) Fibre analysis of the nerve to the inferior oblique muscle in monkeys. *J. Anat.* **137**, 445-455
- Ruskell, G.L. (1984) Spiral nerve endings in human extraocular muscles terminate in motor end plates. *J. Anat.* **139**, 33-44
- Ruskell, G.L. (1989) The fine structure of human extraocular muscle spindle and their potential proprioceptive capacity. *J. Anat.* **167**, 199-214
- Ruskell, G.L. (1990) Golgi tendon organs in the proximal tendon of sheep extraocular muscles. *Anat.Rec.* **227**, 25-31
- Ruskell, G.L. (1999) Extraocular Muscle Proprioceptors and Proprioception. *Pro. Retin. Eye Res. Vol 18*, **3**, 269-291
- Ruskell, G.L. and Wilson, J. (1983) Spiral nerve endings and dapple motor end plates in monkey extraocular muscles. *J. Anat.* **136**, 85-95
- Sadeh, M. and Stern, L.Z. (1984) Observation on the innervation of human extraocular muscles. *J. Neurol. Sci.* **66**, 295-305
- Salpeter, M.M. (1987) The vertebrate neuromuscular junction. In Neurology and Neurobiology (Chan-Palay and Palay eds.), pp 1-54, Alan R. Liss Inc., New York
- Salpeter, M.M., McHenry, F.A. and Feng, H. (1974) Myoneural junctions in the extraocular muscles of the mouse. *Anat. Rec.* **174**, 201-224

- Sas, J. and Appeltauer, C. (1963) Atypical muscle spindles in the extrinsic eye muscles of man. *Acta Anat.* **55**, 311-322
- Sas, J. and Schab, R. (1952) Die sogenannten Palisaden-Endungen der Augenmuskeln. *Acta Morph. Acad. Sci. Hung.* **2**, 259-266
- Saude, T. (1993) Ocular Anatomy and Physiology, Blackwell Scientific Publications Inc., Boston
- Sherrington, C.S. (1906) On the proprioceptive system, especially in its reflex aspect. *Brain* **29**, 467-482
- Sherrington, C.S. (1893) On the anatomical constitution of nerves to skeletal muscles; with remarks on recurrent fibres in the ventral spinal nerve-root. *J. Physiol.* **17**, 211-258
- Sherrington, C.S. (1918) Observations on the sensual role of the proprioceptive nerve-supply of the extrinsic ocular muscles. *Brain* **41**, 332-343
- Shimmelpfennig, B. (1982) Nerve structure in human central corneal epithelium. *Graefes Arch. Clin. Exp. Ophthalmol.* **218**, 14-20
- Schoultz, T.W. and Swett, J.E. (1972) The fine structure of the Golgi tendon organ. *J. Neurocytol.* **1**, 1-25
- Schoultz, T.W. and Swett, J.E. (1973) Ultrastructural organization of the sensory fibres innervating the golgi tendon organs. *Anat. Rec.* **179**, 147-162
- Siebeck, R. and Krüger, P. (1955) Die histologische Structur der ausseren Augenmuskeln als Ausdruck ihrer Funktion. *Graefes Arch. Ophthalmol.* **156**, 637-652
- Silverberg, K.R., Ogilvy, C.S. and Borges, L.F. (1989) A Modified Gold Chloride Technique for Optimal Impregnation of Nerves Within Corneal Whole Mounts and Dura of the Albino Rat. *J. Histochem. Cytochem.* **37**, 269-271
- Skavenski, A.A. (1972) Inflow as a source of extraretinal eye position information. *Vis. Res.* **12**, 221-229
- Snell, R.S. and Lemp, M.A. (1989) Movements of the eyeball and the extraocular muscles. In Clinical anatomy of the eye, pp 209-243, Blackwell Scientific Publications Inc., Boston
- Sodi, A., Corsi, M., Faussone Pellegrini, M.S. and Savi, G. (1988) Fine structure of the receptors at the myotendinous junction of human extraocular muscles. *Histol. Histopath.* **3**, 103-113
- Spencer, R.F. and Porter, J.D. (1981) Innervation and structure of extraocular muscles in the monkey in comparison to those of the cat.

J. Comp. Neur. **198**, 649-665

Spencer, R.F. and Porter, J.D. (1988) Structural organization of the extraocular muscles. In Neuroanatomy of the oculomotor system (Buttner-Ennever ed.), pp 33-79, Elsevier Science Publisher

Stark, L. and Bridgeman, B. (1983) Role of corollary discharge in space constancy. *Perception and Psychophysics* **34**, 371-380

Steer, J.C. and Horney, F.D. (1968) Evidence for passage of cerebrospinal fluid among spinal nerves. *Can. Med. Ass. J.* **98**, 71-74

Stefani, E. and Steinbach, A.B. (1969) Resting potential and electrical properties of frog slow muscle fibres. Effect of different external solutions. *J. Physiol. (Lond.)* **203**, 383-401

Steinacker, A. and Bach-y-Rita, P. (1968) A mechanical study on the cat retractor bulbi muscle. *Experientia* **12**, 1138-1139

Steinbach, M.J. (1986) Inflow as a long-term calibrator of eye position in humans. *Acta Psychol.* **63**, 297-306

Steinbach, M.J. (1987) Proprioceptive knowledge of eye position. *Vis. Res.* **10**, 1737-1744

Steinbach, M.J. and Smith, D.R. (1981) Spatial localization after strabismus surgery: evidence for inflow. *Science* **213**, 1407-1409

Tarkhan, A.A. (1934) The innervation of the extrinsic ocular muscles. *J. Anat.* **68**, 293-313

Teravainen, H. (1968) Electron microscopic and histochemical observations on different types of nerve endings in the extraocular muscles of the rat. *Z. Zellforsch. Mikrosk. Anat.* **90**, 373-388

Teravainen, H. and Huikuri, K. (1969) Effects of oculomotor and trigeminal nerve section on the ultrastructure of different myoneural junctions in rat extraocular muscles. *Z. Zellforsch. Mikrosk. Anat.* **102**, 466-482

Thulin, I. (1914) Histologie des muscles oculaires chez l'homme et les singes. *Compt. Rend. Soc. Biol.* **76**, 490-493

Tozer, F.M. and Sherrington, C.S. (1910) Receptors and afferents of the III, IV and VI cranial nerves. *Proc. Roy. Soc. Lond. Ser. B* **82**, 450-457

Von Noorden, G.K. (1990) Binocular Vision and Ocular Motility (Von Noorden ed.), The C.V. Mosby Company, Toronto

Zelena, J. and Soukup, T. (1977) Development of Golgi tendon organs.


J. Neurocytol. **6**, 447-463

Zenker, W. and Ansenbacher, H. (1964) On the different forms of myo-neural junction in two types of muscle fiber from the external ocular muscles of the rhesus monkey. *J. Cell Comp. Physiol.* **63**, 273-285

Zimny, M.L., St. Onge, M. and Schutte, M. (1985) A modified gold chloride method for demonstration of nerve endings in frozen sections. *Stain Technol.* **60**, 305-306



Høgskolen i Buskerud
Postboks 235
3603 Kongsberg
Telefon: 32 86 95 00
Telefaks: 32 86 98 83
www.hibu.no



HØGSKOLEN
i Buskerud