

Functional and Morphological Evaluation of Meibomian Glands in the Assessment of Meibomian Gland Dysfunction Subtype and Severity



JIAXIN XIAO, MUHAMMED YASIN ADIL, XIANGJUN CHEN, ØYGUNN A. UTHEIM, STEN RÆDER, KIM ALEXANDER TØNSETH, NEIL S. LAGALI, DARLENE A. DARTT, AND TOR P. UTHEIM

- **PURPOSE:** To classify subtypes of meibomian gland dysfunction (MGD) and evaluate the dependency of dry eye signs, symptoms, and parameters on MGD subtype.
- **DESIGN:** Cross-sectional study. **Study Population:** the right eyes of 447 patients with MGD of various subtypes and 20 healthy volunteers.
- **METHODS:** Patients were divided into 4 subtypes of MGD based on meibum expression, meibum quality, and MG loss on meibography images (meibograde of 0–6). Subtypes were patients with high meibum delivery (hypersecretory and nonobvious MGD) and those with low meibum delivery (hyposecretory and obstructive MGD). Additional clinical tests included tear film break-up time (TFBUT), ocular staining, osmolarity, Schirmer I, blink interval timing and the Ocular Surface Disease Index (OSDI) questionnaire.
- **RESULTS:** A total of 78 eyes had hypersecretory MGD; 49 eyes had nonobvious MGD; 66 eyes had hyposecretory MGD; and 254 eyes had obstructive MGD. Increased tear film osmolarity and lower TFBUT were found in the low-delivery groups; hyposecretory ($P = 0.006$, $P = 0.016$) and obstructive MGD ($P = 0.008$, $P = 0.006$) relative to high-delivery MGD (hypersecretory and nonobvious groups, respectively). Worse ocular symptoms and ocular

staining were also found in low-delivery MGD groups than the high delivery MGD groups ($P < 0.01$ and $P < 0.006$, respectively).

- **CONCLUSIONS:** Patients with low-delivery MGD had worse dry eye parameters and ocular symptoms than those with high meibum delivery, indicating the pivotal role of meibum secretion in ocular surface health that should be targeted in MGD therapy. Furthermore, nonobvious MGD cannot be diagnosed using conventional dry eye tests and requires morphologic assessment of meibography images to confirm MG loss. (Am J Ophthalmol 2020;209:160–167. © 2019 The Author(s). Published by Elsevier Inc. This is an open access article under the CC BY-NC-ND license (<http://creativecommons.org/licenses/by-nc-nd/4.0/>).

MEIBOMIAN GLAND (MG) FUNCTION IS ESSENTIAL in maintaining ocular surface health and stability.¹ MG functional abnormalities lead to reduced meibum secretion and/or altered lipid composition, consequently resulting in evaporative dry eye disease (DED).² There is no precise definition of MG dysfunction (MGD) in published papers. MGD is associated with multiple pathological mechanisms, and various subtypes have been described based on anatomic changes, pathophysiological alterations, or the severity of disease.^{2–4} The International Workshop on MGD classifies MGD as low- and high-delivery status, based on the degree of meibum secretion.²

Clinically, hypersecretory (high-delivery) MGD is characterized by the release of large amounts of meibum at the lid margin. It is arguable whether there is a true hypersecretion from MG or the presence of mild obstruction where meibum releases after forceful pressure of the eyelid.⁴ Nonetheless, no remarkable changes in gland structure were noted by meibography in this subtype.⁵ Conversely, a decreased lipid secretion due to either hyposecretion or obstruction indicates low-delivery MGD. Primary hyposecretion of MG is associated with gland atrophy without signs of gland obstruction.² In contrast, obstructive MGD presents with reduced lipid secretion combined with highly

Accepted for publication Sep 10, 2019.

From the Institute of Clinical Medicine (J.X., M.Y.A.), Faculty of Medicine, University of Oslo, Oslo, Norway; Department of Medical Biochemistry (J.X., M.Y.A., K.A.T., T.P.U.), Oslo University Hospital, Oslo, Norway; The Norwegian Dry Eye Clinic (X.C., Ø.A.U., S.R.), Oslo, Norway; Department of Ophthalmology (X.C., N.S.L., T.P.U.), Sørlandet Hospital, Arendal, Norway; Department of Ophthalmology (X.C., T.P.U.), Oslo University Hospital, Oslo, Norway; Institute of Clinical Dentistry/Department of Oral Biology (X.C., T.P.U.), Faculty of Dentistry, University of Oslo, Oslo, Norway; Faculty of Health Sciences (X.C., T.P.U.), National Centre for Optics, Vision and Eye Care, University College of Southeast Norway, Kongsberg, Norway; Department of Plastic and Reconstructive Surgery (K.A.T., T.P.U.), Oslo University Hospital, Oslo, Norway; Department of Clinical and Experimental Medicine (N.S.L.), Linköping University, Linköping, Sweden; Schepens Eye Research Institute (D.A.D.), Massachusetts Eye and Ear Infirmary, Department of Ophthalmology, Harvard Medical School, Boston, Massachusetts, USA; Department of Ophthalmology (T.P.U.), Stavanger University Hospital, Stavanger, Norway.

Inquiries to Jiaxin Xiao, Freserveien 13, 0195 Oslo, Norway; e-mail: jiaxin1.xiao@gmail.com

viscous meibum due to duct orifice inflammation and hyperkeratinization.⁶

The consequence of MGD is tear film instability resulting in dry eye symptoms.⁶ Currently, it is unclear how different subtypes of MGD affect the characteristics of the tear film. Thus, the clinical implications of classifying MGD subtypes are not obvious. In the present study, MGD was divided into proposed subtypes, and the question of how various clinical ocular surface parameters differed among the subgroups of MGD and healthy controls was investigated.

METHODS

THE RIGHT EYES OF 447 PATIENTS WITH MGD DIAGNOSES according to the guidelines from 2011⁷ at the Norwegian Dry Eye Clinic were included in this cross-sectional study. The study was conducted in accordance with the Declaration of Helsinki. The Regional Committee for Medical and Health Research Ethics, Section C, South East Norway (REC) reviewed the use of the data in this study. The REC found the research project “*Evaluation of Data from the Norwegian Dry Eye Clinic*” to be outside the remit of the Act on Medical and Health Research (2008) and therefore could be implemented without specific approval. Written informed consent was obtained from all participants’ prior data collection.

Study patients were randomly selected from all patients seeking consultation due to various ocular symptoms of discomfort consistent with dry eye. All patients were examined at their initial consultation at the clinic by using a standardized protocol including the Ocular Surface Disease Index (OSDI) symptom questionnaire and supplementary clinical tests such as ocular surface staining, tear film break-up time (TFBUT), blink rate, tear film osmolarity, meibography, Schirmer I test, and meibum expressibility and quality. The clinical tests were performed by independent clinicians who were blinded to the classification criteria of MGD subgroups applied in this study. MGD was diagnosed after first diagnosing evaporative DED based on symptoms assessment and tear film parameters. To distinguish MGD from other subtypes of DED, specific assessments were made of meibum expressibility and quality and were evaluated by gland dropout on meibography images. In addition, 20 healthy volunteers without any systemic diseases or pre-existing ocular conditions or symptoms were recruited from the general population through the National Centre for Optics, Vision, and Eye Care as a control group.

• **CLINICAL EXAMINATIONS:** All patients first completed a symptom questionnaire to obtain an OSDI score between 0 (no symptoms) and 100.⁸ The ability of 5 MGs in the central area of the lower eyelid was tested for meibum secretion

after firm digital pressure was applied. The results were scored from 0 to 3 depending on the number of expressible glands found among the 5 central glands, where 0 = all glands expressible; 1 = 3–4 glands expressible; 2 = 1–2 glands expressible; and 3 = no glands expressible (Table 1).⁹ The quality of expressed meibum was scored from 0 to 3, where 0 = clear fluid; 1 = cloudy fluid; 2 = cloudy and particulate fluid; and 3 = opaque, toothpaste-like meibum.¹⁰ The final meibum quality score was the sum of all 8 central MGs in the lower eyelid (Table 1). MGs that were not able to express meibum could affect the results, and this was noted in the patient’s journal.⁷

The Schirmer I test was performed without anesthesia by inserting the test strip in the lateral third of the lower eyelid for 5 minutes.⁷ The TFBUT for each eye was measured for 30 seconds after instillation of 5 µl of 2% fluorescein to the conjunctival sac. Ocular fluorescein staining was analyzed in similar fashion and graded using the Oxford grading system.^{7,11} Blink interval timing was recorded, and tear film osmolarity were evaluated using the TearLab system (TearLab Corp., San Diego, California). The dry eye severity level was graded from 1 to 4 according to the guidelines proposed by the 2007 International Dry Eye Workshop (Table 2).¹²

Meibography images were acquired using the Oculus Keratograph 5 (Oculus, Wetzlar, Germany). Images were analyzed by an independent expert and according to our previously described method (Table 1).¹³ Briefly, loss of the MG was graded using the 4-point meibograde 0 to 3.

TABLE 1. Clinical Parameters and Their Interpretation

Examination	Evaluation
Ocular surface disease index questionnaire	Score from 0 (no dry eye symptoms) to 100 (severe symptoms)
Tear film break-up time	Less than 5 seconds: decreased
Ocular staining score	Nasal conjunctiva (0–3), cornea (0–3), temporal conjunctiva (0–3)
Blinking interval	Less than 10 seconds: decreased
Tear film osmolarity	Higher than 308 mOsmol/L: increased
Meibograde	Grade 0: 0–25% MG loss Grade 1: 26–50% MG loss Grade 2: 51–75% MG loss Grade 3: >75% MG loss Total meibograde (0–6): upper eyelid + lower eyelid
Schirmer’s test	Less than 5 mm: decreased
Meibum expressibility	Score 0: all glands expressible Score 1: 3–4 glands expressible Score 2: 1–2 glands expressible Score 3: no glands expressible

MG = meibomian gland.

TABLE 2. Dry Eye Severity Grading Scheme

Dry Eye Severity Level	1	2	3	4*
Discomfort, severity and frequency	Mild and/or episodic	Moderate episodic or chronic	Severe frequent or constant	Severe and/or disabling and constant
Conjunctival staining	None to mild	Variable	Moderate to marked	Marked
Corneal staining (severity/location)	None to mild	Variable	Marked central	Severe punctate erosions
TFBUT, s	Variable	≤10	≤5	Immediate
Schirmer I score (mm/5 min)	Variable	≤10	≤5	≤2

TFBUT = tear-film breakup time.
*Must have signs AND symptoms.

Meibogrades of upper and lower lids were combined to give 1 score from 0 to 6. Additional measurements of MG length, thickness, density (i.e., the space between 2 adjacent MGs) and number of distorted glands was performed using ImageJ version 2.0.0 software (National Institutes of Health, Bethesda, Maryland). Computerized analyses were performed of the 3 most representative glands in the upper eyelid only.

After the clinical examination, patients were divided into 4 groups by using a novel classification with basis on a combination of previously proposed diagnostic criteria (Figure 1).^{2,7,14} The obstructive MGD group included subjects who fulfilled the previously proposed diagnostic criteria, as follows¹⁴: they had 1) poor meibum secretion (meibum expressibility score ≥1) and 2) altered meibum quality (score >5). Subjects with poor meibum expression (meibum expressibility score ≥1) and minimally altered meibum quality (score ≤5) were then divided into the hyposecretory MGD group.⁷ The hypersecretory MGD group consisted of patients with high meibum expression (meibum expressibility score = 0) and subtle MG loss (meibograde ≤2) (Figure 2).² The remaining patients with high meibum secretion (meibum expressibility score = 0) and moderate to severe MG loss (meibograde >2) formed a separate, undefined MGD group (Figure 2).

• **STATISTICAL ANALYSIS:** Data were analyzed using SPSS version 25.0 software (IBM, Armonk, New York). The data were tested for normal distribution using the Shapiro-Wilk test. Results from the MGD subtype groups and the control group were compared by using pair-wise comparisons and Kruskal-Wallis test with Dunn-Bonferroni post hoc test. The results for all parameters are presented as mean ± standard deviation. A *P* value of <0.05 was considered statistically significant.

RESULTS

SEVENTY-EIGHT EYES (50 WOMEN AND 28 MEN; MEAN AGE OF 42.1 ± 15.1 years old) had hypersecretory MGD; 49 eyes

(28 women and 21 men; mean age: 50.7 ± 15.8 years old) had undefined MGD; 66 eyes (55 women and 11 men; mean age: 51.1 ± 17.2 years old) had hyposecretory MGD; and 254 eyes (199 women and 55 men; mean age: 53.4 ± 15.7 years old) had obstructive MGD. The controls were 20 eyes of 20 healthy volunteers (11 women and 9 men; mean age: 31.7 ± 14 years old).

The clinical parameters in each group of study subjects are presented in Table 3, and the *P* value for pairwise comparisons of clinical parameter and MG parameters are presented in Table 4 and 5, respectively. Compared to the control group, all MGD subgroups had significantly shorter TFBUT and blink intervals (*P* < 0.001 and *P* < 0.001, respectively). The hypersecretory, undefined, and obstructive MGD groups had poorer meibum quality (*P* < 0.001) than the control group. Tear film hyperosmolarity (>308 mOsmol/L) was found in low-delivery MGD groups only (*P* = 0.006 for hyposecretory and *P* = 0.008 for obstructive MGD).

Schirmer I test results did not show any significant differences between subgroups of MGD and the control. Among the MGD subgroups, tear film osmolarity was higher, whereas TFBUT was lower in both the hyposecretory and the obstructive groups than that in hypersecretory and undefined MGD groups (*P* = 0.016 and *P* = 0.006, respectively). The low-delivery MGD groups (hyposecretory and obstructive MGD) had worse ocular symptoms and ocular staining than the high-delivery MGD groups (hypersecretory and undefined MGD; *P* < 0.01 and *P* = 0.006, respectively).

DISCUSSION

IN THE PRESENT STUDY, IT WAS OBSERVED THAT LOW-delivery MGD (hyposecretory and obstructive groups) had tear film hyperosmolarity, shorter TFBUT, and worse ocular staining score and symptom scores than high-delivery MGD groups (hypersecretory and undefined groups). Only marginal differences were found in MGD patients within the same meibum delivery status. A group of

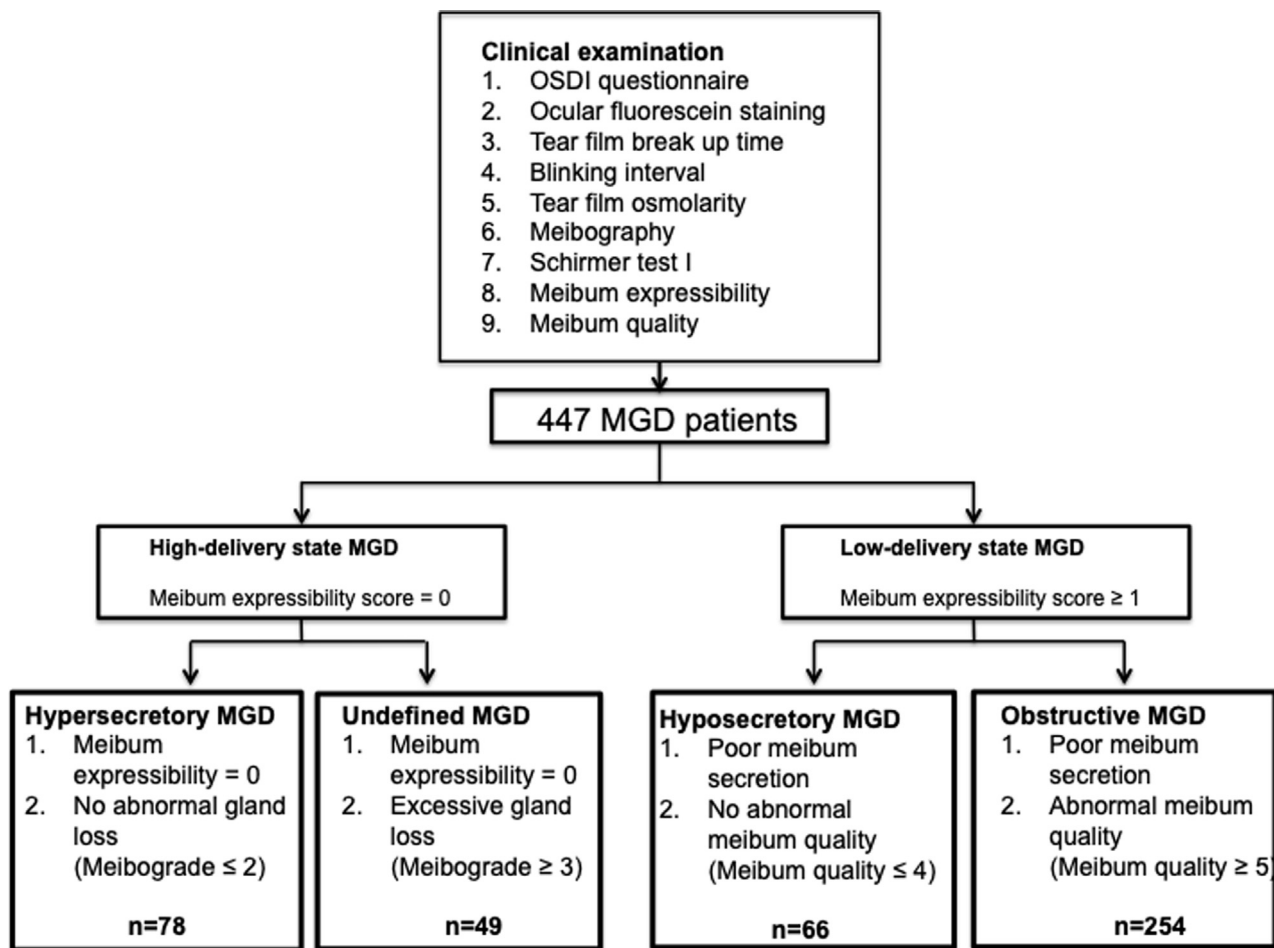


FIGURE 1. Flowchart showing patient progress through the study. MGD = meibomian gland dysfunction; OSDI = Ocular Surface Disease Index.

MGD patients demonstrated severe MG loss with high meibum secretion and did not meet the criteria for any existing MGD subtype, which was believed to be a nonobvious MGD group.

In this study, the nonobvious MGD patients had profound MG loss and structural changes but maintained high meibum secretion and demonstrated meibum quality comparable to that of the patients with hypersecretory MGD. This finding indicates that nonobvious cannot be diagnosed using regular clinical dry eye tests and therefore requires meibography image assessment for a proper diagnostic and subclassification of MGD. Some authors have suggested that the clinical features of hypersecretory MGD result from a damming of secretions due to a partial obstruction and may represent an early stage of obstructive MGD.⁴ The present authors speculate that this explanation might apply to the nonobvious MGD subgroup observed in the present study. In healthy subjects, the secretion from a few MGs is sufficient to maintain a normal lipid secretion.¹⁵ In the nonobvious MGD group with

excessive MG loss, the high meibum expression could be maintained by few but active MGs. Moreover, there may also be a partial obstruction of these active MGs, suggested by the cloudy appearance of expressed meibum. Nevertheless, the present findings suggest that this particular MGD subgroup should be categorized as its own group, hereafter called nonobvious MGD.¹⁵ Together with the fact that the nasally located MGs tends to produce more meibum even after considerable MG loss,¹⁶ the authors hypothesize that the site of MG loss could be a more important characteristic than the overall degree of MG atrophy.

Tear film instability and hyperosmolarity are recognized as 2 core mechanisms of DED.^{17,18} Our study showed that all MGD subgroups had markedly and significantly lower TFBUT (reflects tear film instability) than the control group. The differences among the subtypes of MGD, however, were marginal. Hypersecretory and nonobvious MGD appeared to have slightly but significantly better tear film stability than the other subtypes. Considering that tear film hyperosmolarity is thought to be a result of tear film

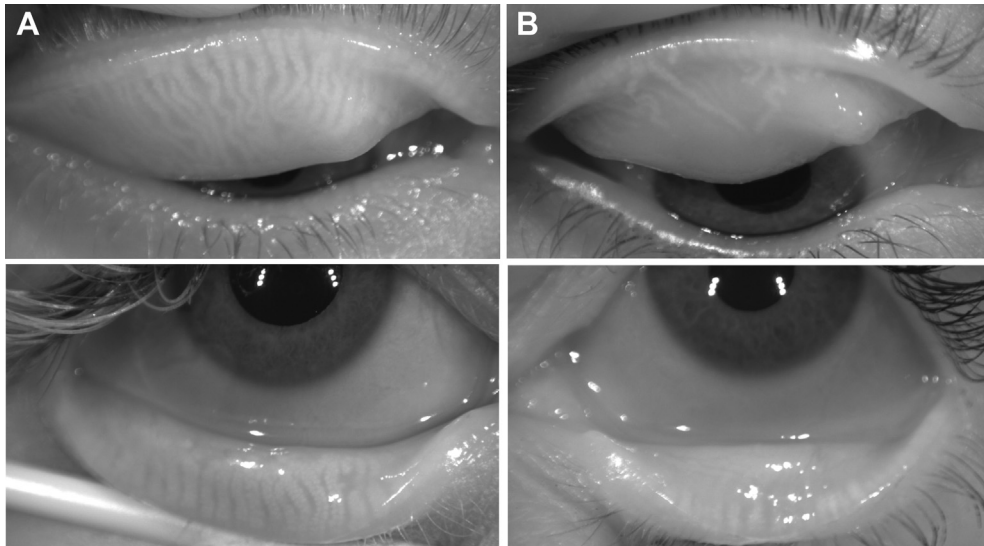


FIGURE 2. Representative noninvasive meibographic images of 2 patients. (A) Meibographic images of the upper and lower eyelids of a hypersecretory MGD patient (meibograde 0 for both eyelids). (B) Images of the upper and lower eyelids of an MGD patient belonging to the undefined subgroup (meibograde 3 for both eyelids). MGD = meibomian gland dysfunction.

TABLE 3. Clinical Parameters in Normal Controls and Each Subtype of Meibomian Gland Dysfunction

Clinical Parameters	Normal Control	Hypersecretory MGD	Undefined MGD	Hyposecretory MGD	Obstructive MGD
Eyes, n	20	78	49	66	254
Age, years	31.7 ± 14.0	42.1 ± 15.1	50.7 ± 15.8	51.1 ± 17.2	53.4 ± 15.7
OSDI score		30.3 ± 19.7	28.7 ± 18.1	41.1 ± 24.1	38.7 ± 22.2
Meibum expression	0.8 ± 0.8	0.0 ± 0.0	0.0 ± 0.0	2.1 ± 0.7	1.7 ± 0.6
Meibum quality	0.03 ± 0.2	8.1 ± 4.1	8.9 ± 4.5	2.6 ± 1.6	10.6 ± 4.4
Ocular staining score	0.9 ± 0.6	1.12 ± 1.4	1.1 ± 1.5	2.0 ± 2.2	1.8 ± 2.1
Tear-film break-up time, s	9.6 ± 9.9	4.6 ± 3.2	4.0 ± 2.7	3.2 ± 1.9	3.4 ± 2.4
Schirmer's test value	16.5 ± 11.9	14.3 ± 8.5	16.2 ± 9.7	15.7 ± 9.8	14.7 ± 9.7
Blink interval, s	19.5 ± 10.0	3.6 ± 2.4	3.1 ± 2.3	3.1 ± 2.2	3.3 ± 4.4
Osmolarity	305.0 ± 10.5	307.7 ± 13.2	307.5 ± 15.6	314.0 ± 13.5	313.2 ± 14.8
Meibograde	0.4 ± 0.5	1.4 ± 0.7	3.9 ± 0.9	3.7 ± 1.7	2.9 ± 1.6
Number of distorted glands	2.7 ± 1.5	1.2 ± 1.3	0.9 ± 1.4	0.8 ± 1.3	0.9 ± 1.3
MG thickness (ImageJ unit)	20.9 ± 3.7	19.7 ± 3.2	19.9 ± 3.9	19.3 ± 4.8	19.1 ± 3.6
MG density (ImageJ unit)	20.2 ± 16.3	15.7 ± 2.7	16.3 ± 3.4	14.8 ± 3.0	15.4 ± 3.1
MG length (ImageJ unit)	298.5 ± 49.2	306 ± 58.4	234.7 ± 85.5	216.6 ± 81.1	254.3 ± 73.6
MG dropout, %	12.6 ± 5.1	18.3 ± 6.8	36.4 ± 15.2	41.3 ± 19.6	32.9 ± 16.7

MGD = meibomian gland dysfunction; OSDI = ocular surface disease index.
ImageJ software (National Institutes of Health, Bethesda, Maryland).

instability, increased osmolarity is expected in all MGD patients.^{19,20} Interestingly, increased tear film osmolarity was found only in hyposecretory and obstructive MGD. The mean osmolarity levels observed in these 2 subgroups were higher than the proposed cutoffs for DED diagnosis.^{18,21} Taken together, these findings indicate that reduced TFBUT is a more prominent characteristic in MGD than increased tear film osmolarity. Furthermore,

only low-delivery MGD met the criteria of dry eye, which questions the diagnostic role of tear film osmolarity in evaporative DED where MGD may be suspected.^{18,21}

The low-delivery MGD subgroups had significantly higher ocular symptom scores and ocular staining scores than the high-delivery subgroups. A discrepancy is described between the intensity of subjective symptoms and signs of ocular surface damage in patients with

TABLE 4. Pairwise Comparisons of Clinical Parameters between Normal Controls and Each Subgroups of Meibomian Gland Dysfunction

Parameter		OSDI Score	Age	DESL	Ocular Staining Score	Tear-Film Break-up Time	Schirmer's Test Value ^a	Blink Interval	Tear Osmolarity
Normal vs.	Hypersecretory MGD	-	-	-	0.71	0.001		<0.001	0.42
	Undefined MGD	-	-	-	0.64	< 0.001		< 0.001	0.78
	Hyposecretory MGD	-	-	-	0.06	< 0.001		< 0.001	0.006
	Obstructive MGD	-	-	-	0.28	< 0.001		< 0.001	0.008
Hypersecretory MGD vs.	Undefined MGD	0.71	0.04	0.58	0.85	0.3		0.20	0.6
	Hyposecretory MGD	0.02	< 0.01	< 0.001	0.001	0.006		0.11	0.016
	Obstructive MGD	0.008	< 0.001	0.11	0.006	0.002		0.4	0.014
Undefined vs.	Hyposecretory MGD	0.01	0.8	0.02	0.001	0.1		0.85	0.008
	Obstructive MGD	0.01	0.27	0.14	0.01	0.35		0.82	0.009
Hypersecretory MGD	Obstructive MGD	0.63	0.36	0.11	0.68	0.96		0.99	0.36

DESL = dry eye severity level; MGD = meibomian gland dysfunction; OSDI = ocular surface disease index.

- = Data were obtained from the control group due to irrelevance.

P values in bold indicate significance.

^aKruskal-Wallis test did not find significant difference between groups.

TABLE 5. Pairwise Comparison of Meibomian Gland Parameters between Normal Controls and Each Subgroup of Meibomian Gland Dysfunction

Meibomian Gland Parameter		Meibo expressibility	Meibum Quality	Meibograde	Number of Distorted Gland	MG Thickness	MG Density	MG Length
Normal vs.	Hypersecretory MGD	<0.001	<0.001	0.154	<0.001	0.09	0.43	0.82
	Undefined MGD	<0.001	<0.001	<0.001	<0.001	0.33	0.45	0.001
	Hyposecretory MGD	<0.001	0.19	<0.001	<0.001	0.13	0.007	<0.001
	Obstructive MGD	<0.001	<0.001	<0.001	<0.001	0.052	0.052	0.005
Hypersecretory MGD vs.	Undefined MGD	1.0	0.68	<0.001	0.13	0.35	0.30	<0.001
	Hyposecretory MGD	0<0.001	<0.001	<0.001	0.02	0.20	0.11	<0.001
Undefined vs.	Obstructive MGD	<0.001	0.005	<0.001	0.04	0.09	0.14	<0.001
	Hyposecretory MGD	<0.001	<0.001	0.25	0.83	0.40	0.14	0.31
Hypersecretory MGD	Obstructive MGD	<0.001	0.09	<0.001	0.62	0.08	0.10	0.12
	Obstructive MGD	0.046	<0.001	0.012	0.39	0.95	0.52	0.017

MG= meibomian gland; MGD = meibomian gland dysfunction.

P values marked in bold indicate significance.

MGD.²² However, patients with various subtypes of MGD were usually investigated collectively. By dividing patients into subgroups of MGD, the data revealed more severe ocular epithelial damage in MGD patients with reduced meibum expression (hyposecretory and obstructive MGD) and highlights the effects of the vicious circle in dry eye where damage of tear film is connected in a cyclical manner.²³ The relationship between higher ocular symptoms score and reduced meibum secretion is unclear. Some of the subjective symptoms are likely linked to increase in tear film osmolarity due to poor tear film lipid layer, as suggested previously.²⁴ Of note, the hyposecretory

MGD group had the highest OSDI score, suggesting that the actual secretory activity of MG may be an important factor in the development of ocular symptoms.

Herein, all patients had significantly higher meibograde and markedly fewer distorted glands than the control subjects. The fact that healthy subjects in this study were not age-matched limits the interpretation of the comparison with healthy controls, as age is a known risk factor for structural changes of MGs.²⁵⁻²⁷ Among the MGD groups, MG loss was significantly less in patients with hypersecretory MGD than in patients with low-delivery status (hyposecretory and

obstructive MGD), which is consistent with a previous study.⁵

There were no significant differences in Schirmer test values among the subtypes of MGD and control group, nor among MGD subgroups. The Schirmer test measures reflex tear fluid production,²⁸ and the results demonstrated that the tear production is sustained in MGD, which appears reasonable, as the aqueous volume of tear film is not related to MG function. However, there could also be a secondary compensated increased tear production as suggested in the previous papers.²² Furthermore, we observed a significantly shortened blink interval in all MGD subgroups, which is likely related to reduced

TFBUT and compensates for early tear film evaporation.^{12,29}

In conclusion, patients with low-delivery MGD had significantly worse dry eye parameters and ocular symptoms than the patients with high meibum delivery, indicating that reduced meibum secretion is a major contributor to the poor ocular surface condition and should be a target of therapeutic interventions. Moreover, patients with nonobvious MGD present only with excessive MG loss that cannot be diagnosed using conventional clinical dry eye tests. The assessment of gland atrophy on meibography images is therefore required for a proper diagnostic subclassification of MGD.

Acknowledgements

ALL AUTHORS HAVE COMPLETED AND SUBMITTED THE ICMJE FORM FOR DISCLOSURE OF POTENTIAL CONFLICTS OF INTEREST and none were reported. Funding/support: This research did not receive any specific grant from funding agencies in the public, commercial, or not-for-profit sectors. Financial disclosures: The authors indicate no financial support or financial conflict of interest.

REFERENCES

1. Wang J, Call M, Mongan M, Kao WW, Xia Y. Meibomian gland morphogenesis requires developmental eyelid closure and lid fusion. *Ocul Surf* 2017;15:704–712.
2. Nelson JD, Shimazaki J, Benitez-del-Castillo JM, et al. The international workshop on meibomian gland dysfunction: report of the definition and classification subcommittee. *Invest Ophthalmol Vis Sci* 2011;52:1930–1937.
3. Shimazaki J, Sakata M, Tsubota K. Ocular surface changes and discomfort in patients with meibomian gland dysfunction. *Arch Ophthalmol* 1995;113:1266–1270.
4. Foulks GN, Bron AJ. Meibomian gland dysfunction: a clinical scheme for description, diagnosis, classification, and grading. *Ocul Surf* 2003;1:107–126.
5. Arita R, Itoh K, Maeda S, et al. Proposed diagnostic criteria for seborrhic meibomian gland dysfunction. *Cornea* 2010;29:980–984.
6. Knop E, Knop N, Millar T, Obata H, Sullivan DA. The international workshop on meibomian gland dysfunction: report of the subcommittee on anatomy, physiology, and pathophysiology of the meibomian gland. *Invest Ophthalmol Vis Sci* 2011;52:1938–1978.
7. Tomlinson A, Bron AJ, Korb DR, et al. The international workshop on meibomian gland dysfunction: report of the diagnosis subcommittee. *Invest Ophthalmol Vis Sci* 2011;52:2006–2049.
8. Schiffman RM, Christianson MD, Jacobsen G, Hirsch JD, Reis BL. Reliability and validity of the ocular surface disease index. *Arch Ophthalmol* 2000;118:615–621.
9. Pflugfelder SC, Tseng SC, Sanabria O, et al. Evaluation of subjective assessments and objective diagnostic tests for diagnosing tear-film disorders known to cause ocular irritation. *Cornea* 1998;17:38–56.
10. Bron AJ, Benjamin L, Snibson GR. Meibomian gland disease. Classification and grading of lid changes. *Eye (Lond)* 1991;5(Pt 4):395–411.
11. Bron AJ, Evans VE, Smith JA. Grading of corneal and conjunctival staining in the context of other dry eye tests. *Cornea* 2003;22:640–650.
12. The definition and classification of dry eye disease: report of the Definition and Classification Subcommittee of the International Dry Eye WorkShop (2007). *Ocul Surf* 2007;5:75–92.
13. Adil MY, Xiao J, Olafsson J, et al. Meibomian gland morphology is a sensitive early indicator of meibomian gland dysfunction. *Am J Ophthalmol* 2019;200:16–25.
14. Arita R, Itoh K, Maeda S, et al. Proposed diagnostic criteria for obstructive meibomian gland dysfunction. *Ophthalmology* 2009;116:2058–2063.e2051.
15. Blackie CA, Korb DR, Knop E, Bedi R, Knop N, Holland EJ. Nonobvious obstructive meibomian gland dysfunction. *Cornea* 2010;29:1333–1345.
16. Ngo W, Srinivasan S, Jones L. A comparison of dry eye diagnostic tests between symptomatic and asymptomatic age-matched females. *Eye Contact Lens* 2018;44(Suppl 1):S110–S114.
17. Craig JP, Nelson JD, Azar DT, et al. TFOS DEWS II report executive summary. *Ocul Surf* 2017;15:802–812.
18. Potvin R, Makari S, Rapuano CJ. Tear film osmolarity and dry eye disease: a review of the literature. *Clin Ophthalmol* 2015;9:2039–2047.
19. Wu H, Lin Z, Yang F, et al. Meibomian gland dysfunction correlates to the tear film instability and ocular discomfort in patients with pterygium. *Sci Rep* 2017;7:45115.
20. King-Smith PE, Ramamoorthy P, Braun RJ, Nichols JJ. Tear film images and breakup analyzed using fluorescent quenching. *Invest Ophthalmol Vis Sci* 2013;54:6003–6011.
21. Jacobi C, Jacobi A, Kruse FE, Cursiefen C. Tear film osmolarity measurements in dry eye disease using electrical impedance technology. *Cornea* 2011;30:1289–1292.
22. Arita R, Morishige N, Koh S, et al. Increased tear fluid production as a compensatory response to meibomian gland

- loss: a multicenter cross-sectional study. *Ophthalmology* 2015; 122:925–933.
23. Baudouin C, Messmer EM, Aragona P, et al. Revisiting the vicious circle of dry eye disease: a focus on the pathophysiology of meibomian gland dysfunction. *Br J Ophthalmol* 2016;100:300–306.
 24. Foulks GN. The correlation between the tear film lipid layer and dry eye disease. *Surv Ophthalmol* 2007;52: 369–374.
 25. Arita R, Itoh K, Inoue K, Amano S. Noncontact infrared meibography to document age-related changes of the meibomian glands in a normal population. *Ophthalmology* 2008;115:911–915.
 26. Ban Y, Shimazaki-Den S, Tsubota K, Shimazaki J. Morphological evaluation of meibomian glands using noncontact infrared meibography. *Ocul Surf* 2013;11:47–53.
 27. Yeotikar NS, Zhu H, Markoulli M, Nichols KK, Naduvilath T, Papas EB. Functional and morphologic changes of meibomian glands in an asymptomatic adult population. *Invest Ophthalmol Vis Sci* 2016;57:3996–4007.
 28. Senchyna M, Wax MB. Quantitative assessment of tear production: A review of methods and utility in dry eye drug discovery. *J Ocul Biol Dis Infor* 2008;1:1–6.
 29. Inomata T, Iwagami M, Hiratsuka Y, et al. Maximum blink interval is associated with tear film breakup time: a new simple, screening test for dry eye disease. *Sci Rep* 2018;8:13443.